



**ida**

Indian Dental Association  
Madras Branch

# **E - MIDAS JOURNAL**

**“An Official Journal of  
IDA - Madras Branch”**

**Chennai/Volume:2/Issue:3/Pages:1-46/October2015**

**[www.idamadrass.com](http://www.idamadrass.com)**

# CONTENTS

|   |              |
|---|--------------|
| <b>1. PRESIDENT'S MESSAGE</b>   | <b>1</b>     |
| <b>2. SECRETARY'S MESSAGE</b>   | <b>2</b>     |
| <b>3. EDITOR'S MESSAGE</b>  | <b>3</b>     |
| <b>4. EDITORIAL BOARD</b>   | <b>4</b>     |
| <b>5. EDITORIAL</b>   | <b>5</b>     |
| <b>6. REVIEW</b>  |              |
| 6.1 Granulomatous Diseases of Orofacial Region – A Review<br><i>- N.Vaishnavi Dhanvantri, R.A.Anita Priya, N.Aishwarya Lakshmi, G.M.Sudarsan</i>  | <b>6-11</b>  |
| 6.2 Myofibroblasts in Oral Health and Disease - <i>Srikanth</i>   | <b>12-15</b> |
| 6.3 Low intensity pulsed ultrasound in periodontal regeneration<br><i>- S.Gopalakrishnan, Parthiban Saket, V.Shankarram</i>   | <b>16-18</b> |
| 6.4 Electrosurgery applications in dental practice<br><i>- Dinesh CC, Sri Vandana T, Vamsi Lavu, S.K. Balaji</i>  | <b>19-20</b> |
| 6.4 A review of Probiotics in treating oral microbial infections<br><i>- Manikandan Kumaraswamy, Ramalakshmi M, Md. Abdul Rahim Akbar</i>   | <b>24-26</b> |
| <b>7. CASE REPORTS</b>  |              |
| 7.1 Herpes Virus 1 - A Hidden Culprit in Perimplant Mucositis - A Case Report<br><i>- Parthiban Saket, S.Gopalakrishnan, V.Shankarram</i>   | <b>21-23</b> |
| <b>8. ORIGINAL PAPERS</b>   |              |
| 8.1 Knowledge and attitude regarding the use of conscious sedation for dental procedures among the interns of dental colleges in Chennai city – A cross sectional survey - <i>Yamuna V, Lalithambigai G, Madan Kumar PD</i> | <b>27-29</b> |
| <b>9. ADVERTISEMENT &amp; PLACEMENT CELL</b>  | <b>30-31</b> |
| <b>10. BRANCH ACTIVITIES JULY - OCTOBER 2015</b>  | <b>32-43</b> |

# PRESIDENT'S MESSAGE



**Dr. Vidyaa Hari Iyer**  
President  
IDA Madras Branch

It gives me great honor to release the Third e- Midas Journal for the year 2015 of the prestigious IDA Madras branch. The Editorial team headed by Dr C.K. Dilip Kumar and his associate editors have worked in tandem to release a fantabulous journal. More articles have poured in from the General Practitioners, Research Academicians and Students which shows the growing popularity of our journal. Its a proud moment for all the members of our branch as this journal has been allotted ISSN number.

IDA Madras branch has been a forerunner in setting benchmark and rising the standards in all its activities mainly in the field of academics providing world class Continuing Dental Education programs on a monthly basis along with hands-on and workshops in all subjects of Dentistry, organizing Conferences of International standards such as HANOCON , GDM , FDI series showcasing academic excellence by our very own stalwarts and definitely exhibiting commitment to academic, research and enhancement of clinical acumen by means of publications. I would like to appreciate the CDE Committee Dr Priya Prabakar and her team for their contribution towards the success of all the events and encourage active participation in all our future deliberations. I extend a warm invitation to all the students to participate in large numbers for the MIDAS Scientific convention and all forthcoming academic events.

I would like to take this opportunity to personally thank all the contributing authors for their time and efforts. I would like to personally congratulate Dr Thamilchelvan and all the EC members for their untiring efforts for an action packed year in 2015 working towards a common goal and being united as a team.

I wish the editorial team great success in all their future endeavors.

**Dr. Vidyaa Hari Iyer**

# SECRETARY'S MESSAGE



**Dr. H. Thamizhchelvan**  
Hon. Branch Secretary  
IDA - Madras Branch

Greetings to all,

Love provided by mother will never change throughout her lifetime, In accordance updating our knowledge should continue throughout our career.

IDA Madras takes pride in saying that we constantly conduct many education programmes and to reach on your desk this e Midas journal fulfils thirst of knowledge.

on behalf of IDA - Madras Branch let me congratulate the enthusiastic editorial team on release of this third issue.

**Dr. H. Thamizhchelvan**

# LETTER FROM THE EDITOR



**Dr. C.K. Dilip Kumar**  
Editor-in-Chief  
IDA - Madras Branch

*Knowledge is of no value unless you put it into practise !!!*

I am glad to inform that after a period of time our association journal has received the e-ISSN (International Standard Serial Number) from NISCAR. Our team is working towards getting our e-journal indexed by various indexing bodies. This time there were plenty of manuscripts submitted from students to professors from various colleges in Chennai. I sincerely thank all the contributors and also my editorial team for their efforts towards the up streaming of our journal. We welcome and encourage students and faculty to continue writing ethical manuscripts for publication process.

A handwritten signature in blue ink, appearing to read 'C.K. Dilip Kumar'.

**Dr. C.K. Dilip Kumar**

# EDITORIAL BOARD

## EDITOR-IN-CHIEF



Dr. C.K. Dilip Kumar

## ASSOCIATE EDITORS



Dr. R. Ramya



Dr. Aby John



Dr. Priyanka Cholan

## ASSISTANT EDITORS



Dr. R. Bhavani



Dr. Md. Abdul Rahim Akbar



Dr. Jeshly Joshua



Dr. P. Elavenil

# EDITORIAL

## Electronic Apex Locators - A Guide to the end

The success of an endodontic treatment depends greatly on the removal of all pulp tissue, necrotic material and microorganisms from the root canal. This can only be achieved if the length of the tooth and the root canal is determined with accuracy. The glossary of endodontic terms defines working length as 'the distance from a coronal reference point to the point at which canal preparation and obturation should terminate'. The cementodentinal junction (CDJ) is the anatomical and histological landmark where the periodontal ligament begins and the pulp ends. Root canal preparation techniques aim to make use of this potential natural barrier between the canal contents and apical tissues. It is generally accepted that the preparation and obturation of the root canal should be at or short of this apical constriction. Traditionally, the point of termination for endodontic instrumentation and obturation has been determined by taking radiographs. However radiographs cannot accurately determine the CDJ and arbitrary calculations have to be made to determine the root apex by also taking into consideration the radiographic errors such as foreshortening and elongation.

The development of the electronic apex locator (EAL) has helped make the assessment of working length more accurate and predictable. The glossary of endodontic terms defines an EAL as 'An electronic instrument used to assist in determining the root canal working length or perforation; operates on the principles of resistance, frequency or impedance'.

In the early 1940's Suzuki studied the flow of direct current and registered consistent values in electrical resistance between an instrument in a root canal and an electrode on the oral mucous membrane and speculated that this would measure the canal length. Sunada used these principles in the construction of a simple device that used direct current to measure the canal length. It worked on the principle that the electrical resistance of the mucous membrane and the periodontium registered 6.0 k $\Omega$  in any part of the periodontium regardless of the person's age or the shape and type of teeth.

The first generation EAL's used the resistance method and alternating current as a 150 Hz sine wave but pain was often felt due to high level of currents used. However, these devices were unreliable when compared with radiographs, with many of the readings being significantly longer or shorter than the accepted working length. Thus the second generation EAL's evolved which were of the single frequency impedance type which used impedance

measurements instead of resistance to measure location within the canal by using different frequencies. The voltage gradient method could measure with conductive fluids present but was limited by the presence, absence and location of a constriction and the electrode would not fit in a narrow canal. To overcome these limitations, the third generation EAL's were developed which were similar to the second generation except that they use multiple frequencies to determine the distance from the end of the canal.

Currently the fourth generation EAL's and its successors are widely used all over the world in the field of endodontics. These devices have been refined by many years of research and development to overcome the limitations and drawbacks of its predecessors. These are extremely sophisticated yet simple to use devices which assure an accuracy rate of over 94% in determining the root apex whatever be the clinical scenario (Wet, dry, calcifications etc). All modern apex locators are designed to detect root perforations to clinically acceptable limits and are equally able to distinguish both large and small perforations. Multiple-function apex locators are becoming more common and several have vitality testing functions.

Combining EAL's and electric handpieces are also becoming common and are able to achieve excellent results with the same accuracy as the stand-alone units.

The CDJ is a practical and anatomic termination point for the preparation and obturation of the root canal and this cannot be determined radiographically. Anatomical knowledge of root apex, prudent use of radiographs and the correct use of an electronic apex locator will assist practitioners to achieve predictable results and good endodontic prognosis.

**Dr. Aby John**  
Associate Editor,  
e-MIDAS Journal



# Granulomatous Diseases of Orofacial Region – A Review

N.Vaishnavi Dhanvantri<sup>1</sup>, R.A.Anita Priya<sup>2</sup>, N.Aishwarya Lakshmi<sup>3</sup>, G.M.Sudarsan<sup>4</sup>

1,2,3,4 Post Graduate Student  
Department of Oral and  
Maxillofacial Pathology,  
SRM Dental College and Hospital,  
Ramapuram,  
Chennai

Received : 07.09.2015

Review Completed : 28.09.2015

Accepted : 10.10.2015

## ABSTRACT

Granulomatous diseases encompass a large family of disorders, sharing the histological denominator of granuloma formation. The granulomatous diseases of the head and neck are very unique entities that can mimic or hide malignant tumors and a wide assortment of diseases. They can cause a wide range of signs and symptoms in the head and neck region and also throughout the body. It poses a diagnostic dilemma for the clinician. The frequency of infectious granulomatous diseases is increasing with the increasing incidence of AIDS, multi-drug resistance and with the widespread use of immunosuppressive drugs. It is essential to find the etiology of the disease and to recognize the granulomatous pattern in a biopsy specimen. Thus, a thorough history and a complete physical examination, along with radiological, histological and laboratory evaluation may be required for the correct identification of the granulomatous disease for its specific treatment. In this review, we have highlighted the features of the various granulomatous diseases of the orofacial region that are caused by diverse immunologic, idiopathic, neoplastic, infectious, and fungal processes and their diagnostic procedures.

## Introduction

Granulomatous diseases include a large family of disorders, sharing the histological denominator of granuloma formation. 'Granuloma' is defined as a tiny circumscribed lesion, that is about 1 mm in diameter, and is predominantly composed of collection of modified macrophages called epithelioid cells, and are rimmed at the periphery by lymphoid cells. It is an attempt to wall off substances, the body perceives as foreign but is unable to eliminate.<sup>1</sup> The granulomatous diseases of the head and neck are very unique entities that can mimic or hide malignant tumors and a wide assortment of diseases. The frequency of infectious granulomatous diseases is increasing with the increasing incidence of AIDS, multi-drug resistance and with the widespread use of immunosuppressive drugs. Their diagnosis is usually simple, and does not require complicated diagnostic procedures, but a high degree of suspicion is essential. The microbiological and histopathological analyses are the most specific studies that aid in the diagnosis of granulomatous diseases, but other diagnostic procedures and studies, are helpful to suggest the diagnosis or to define the extent of the disease.<sup>1,2</sup>

## Classification of Granulomatous Diseases, Based on Etiology<sup>3,4,5,28</sup>

### 1) Infection

- a. Bacterial: Tuberculosis, Leprosy, Non-tuberculous mycobacterial infections, Actinomycosis, Klebsiella rhinoscleromatis, Anthrax, Brucellosis, Cat scratch disease
- b. Fungal: Histoplasmosis, Blastomycosis, Mucormycosis, Candidiasis, Cryptococcosis, Rhinosporidiosis
- c. Spirochetal: Syphilis
- d. Parasitic: Leishmaniasis, Myiasis, Toxoplasmosis

### 2) Traumatic Etiology

- i) Pyogenic granuloma
- ii) Reparative granuloma

### 3) Foreign Body Etiology

- i) Oral foreign body reactions (Suture, hair, amalgam, endodontic sealer, hyaluronic acid etc.)
- ii) Cholesterol granuloma
- iii) Cocaine induced midline granuloma

### iv) Gout

### 4) Neoplastic

#### I) Histiocytosis X

- a) Eosinophilic granuloma
- b) Hand schuller Christian Disease.
- c) LettererSiwe disease.

#### ii) Benign Fibrous histiocytoma

#### iii) Neorotizing sialometaplasia.

#### iv) Polymorphic reticulosis (lethal midline granuloma)

### 5) Unknown Etiology

#### i) Sarcoidosis,

#### ii) Crohn's disease

### 6) Autoimmune & Vascular disease

#### i) Wegener's Granulomatosis

#### ii) Systemic Lupus erythematoses

#### iii) Sjogren's syndrome

### 7) Developmental

#### i) Melkerson Rosenthal syndrome

### 8) Congenital chronic Granulomatous disease of Childhood

## Tuberculosis (TB)

Tuberculosis is a chronic granulomatous disease caused by Mycobacterium Tuberculosis. It is classified as – Pulmonary and Extra pulmonary (Lymph nodes, pleura, bones, joints, meninges, genitourinary tract, skin and peritoneum). The Head and neck TB involves larynx, middle ear nasal cavity, nasopharynx, oral cavity, parotid gland, oesophagus and spine.

Oral manifestations of TB is rare (0.1 -5 % of all TB infections) but the incidence is increasing due to the outbreak and emergence of multi drug-resistant TB and emergence of AIDS. Relative resistance of oral cavity to tuberculosis is due to presence of saliva, presence of saprophytes, and resistance of striated muscles to bacterial invasion and thickness of protective epithelial covering. Factors that facilitate invasion include small breaches in the surface epithelium (poor oral hygiene/irritation /local



trauma, self inoculation by infected sputum, Hematogenous /lymphatic dissemination and cases of immunosuppression like AIDS.<sup>6,7</sup> The oral manifestations of tuberculosis are highlighted in Figure 1. Tuberculosis of the oral cavity mimics cancerous lesions and others like traumatic ulcers, aphthous ulcers, actinomycosis, syphilitic ulcer, or Wegener's granuloma. Thus, the chronic indurated ulcer has to be carefully distinguished from a carcinoma.

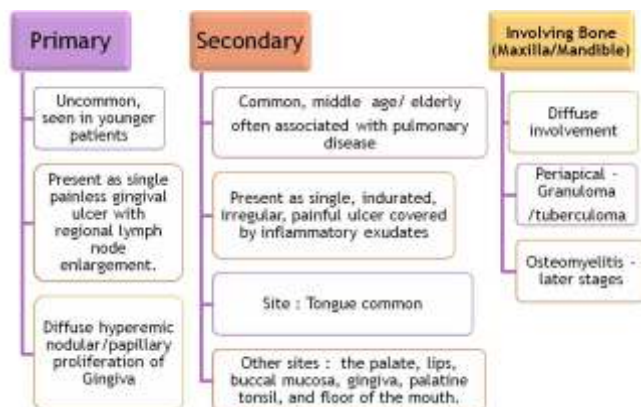


Figure 1: Oral manifestations of Tuberculosis

Histopathologically, tuberculous granulomas are composed of epithelioid cells surrounded by a zone of fibroblasts & lymphocyte that usually contains langhans giant cells some necrosis (caseation) is usually present in the center of the tubercles.<sup>8,9</sup> The investigations for tuberculosis include biopsy, special microbial stains, radiological examination of chest, Mantoux skin test, fine-needle aspiration cytology for identifying TB in major salivary gland. Definitive diagnosis requires isolation and identification of *Mycobacterium tuberculosis* in the Sputum. The first line Drugs most commonly used are Rifampicin, Isoniazid, Ethambuto, Pyrazinamide and Streptomycin.<sup>10</sup>

## Hansen's Disease or Leprosy

Leprosy is caused by *Mycobacterium leprae*. It is a slowly progressive infectious disease that affects skin & peripheral nerves, resulting in disabling deformities. Cell-mediated immunity plays an important part in the pathogenesis of the disease. Mode of Transmission includes direct contact, materno-foetal transmission and through breast milk. Types of Leprosy are Indeterminate, Tuberculoid, Borderline and Lepromatous leprosy. Oral Manifestations of leprosy include ulcers, perforations and scars, papules, nodules (lepromas) and superficial erosions in palate, tongue, uvula, lips and gums. Gingival hyperplasia with loosening of teeth and Paralysis of facial and maxillary division of trigeminal nerve may be seen. Dental manifestations are called Odontodysplasia leprosa. Long standing lepromatous lesions may cause granulomatous invasion of the pulp and pinkish discoloration of crowns. Oral mucosal lesions are sources of infection in lepromatous patients.<sup>11</sup>

*Histopathologically*, the typical Granulomatous nodule consists of epithelioid cells & lymphocytes in a fibrous stroma. Langhans type giant cells and lepra cells are present, that contain the bacilli. The type of inflammatory

reaction depends on the state of the patient's immune system. *Lepromatous* reaction occurs if an adequate T-lymphocyte response is lacking and *Tuberculoid* reaction is seen when the T-cell immunity remains intact, but is functionally unable to fully eliminate the bacteria.<sup>9</sup> Investigations for leprosy include Acid-fast (Ziehl-Neelsen) staining, Fite-Faraco staining procedure, Gomori methenamine silver (GMS) staining PCR, ELISA and IgM antibodies to PGL-1 antigen. Treatment includes Multi drug therapy – Rifampicin, Dapsone, clofazimine.<sup>1</sup>

## Actinomycosis

Actinomycosis is a chronic suppurative disease that is caused by *Actinomyces israelii* – an anaerobic bacterium. There are 4 types depending upon the anatomic location of lesions: cervicofacial, thoracic, abdominal, and pelvic actinomycosis. Cervicofacial actinomycosis is the commonest form (60%) and it is known to have the best prognosis. The tonsils, carious teeth, periodontal disease or trauma following tooth extraction facilitate entry of infection. A firm swelling develops in the lower jaw ('lumpy jaw') initially. As time passes, the mass breaks down leading to formation of abscesses and sinuses. The pus discharge contains typical tiny yellow sulphur granules. The actinomycotic infection may extend into adjoining soft tissues and can also destroy bone.<sup>12</sup>

Histopathologically, the actinomycotic granuloma appears as an isolated mass of Granulomatous inflammatory response or multiple suppurative fields with a central area of suppurative necrosis. Masses of filaments (sulphur granules) extend in a radiating fashion giving it a "sunburst radiation" or fiery appearance. The central core stains basophilic & the peripheral clubs stains eosinophilic with H & E stain. The colonies are surrounded by polymorphonuclear infiltration. Surrounding these inflammatory focus there are plasma cells, lymphocytes, multinucleated giant cells, macrophages and a fibrous capsule are usually seen. The organisms are gram-positive filaments, non acid-fast, and stain positively with Gomori's methenamine silver (GMS) staining.<sup>5,9</sup>

## Cat Scratch Disease

The Causative organism is *Bartonella hensalae*, a gram negative bacillus (demonstrated by silver stain). It is most common in children and young adults. It is caused by traumatic break in skin due to scratch or bite of house hold cat. The primary lesion could be a papule, pustule or vesicle at site of injury. In about 1-3 weeks, painful regional lymphadenitis occurs, that may persist for 1-6 months. Other signs and symptoms include fever, headache, chills, parotid swellings, conjunctivitis, localised granuloma of eye and preauricular lymphadenopathy. Atypical manifestations of the disease lack the characteristic superficial lymphadenopathy and inoculation site papule and may be misdiagnosed initially as other infectious processes or neoplasms. Histopathologically, in early stage, reticuloendothelial hyperplasia are seen in lymph nodes. Later, destruction of lymph node architecture with focal granulomas, suppuration, necrosis with capsular thickening are seen. Epithelioid cells and multinucleated

giant cells are seen at times. Warthin Starry Silver staining and Brown Hopps Gram staining can be used to demonstrate the bacillus. It is a self limiting disease that regresses within a period of weeks and months.<sup>13</sup>

## Syphilis

Syphilis is a venereal (sexually-transmitted) disease caused by spirochaetes, *Treponema pallidum*. The modes of transmission include sexual intercourse, intimate person-to-person contact, transfusion of infected blood and materno-foetal transmission. There are two types of Syphilis - Acquired Syphilis and Congenital syphilis. Primary syphilis present as solitary ulcers with indurated margins on lip, tongue and palate. The ulcers may be deep and are accompanied by cervical lymphadenopathy. The Chancre heals within 7 days to 2 months. Microscopically, it appears as a superficial ulcer with intense inflammatory cell infiltrate and numerous plasma cells. Mucous patches form the characteristic feature of secondary syphilis. These are painless, oval to crescentic erosions surrounded by red periphery. The maculopapular rashes and nodular mucosal lesions can be seen on lips, oral mucosa, tongue, palate and pharynx. The tertiary syphilis is characterised by Gumma formation. Swellings/nodular masses can be seen that may ulcerate resulting in bone destruction, palatal perforation and oro nasal fistula. Atrophic glossitis is also commonly seen. Microscopically, focal granulomatous inflammation with central necrosis can be seen. Congenital syphilis, is characterised by Hutchinson teeth, Mulberry molars, Frontal bossing, saddle nose, and poorly developed maxilla. The Hutchinson's triad includes hypoplasia of the incisor and molar teeth, eighth nerve deafness and interstitial keratitis.<sup>14</sup> Investigations for syphilis include dark ground illumination, fluorescent antibody technique, silver impregnation techniques, PCR and serological tests for syphilis. Penicillin is the drug of choice for syphilis. Other drugs include doxycycline, erythromycin stearate and Ceftriaxone.<sup>10,14</sup>

## Blastomycosis

Blastomycosis is caused by *Blastomyces dermatidis*, a dimorphic fungus that grows in soil and decaying wood. Three clinical forms are present Pulmonary, Disseminated blastomycosis and Cutaneous blastomycosis. Pulmonary blastomycosis can be Acute or Chronic. Acute blastomycosis presents with productive cough, chest pain, dyspnoea, fever, night sweats. Chronic type may be mistaken for TB at times. A pyogranulomatous response is seen at the initial site of pulmonary infection and at any sites of distant spread.<sup>15</sup> Oral involvement can be present as ulcers or exophytic mucosal lesions but is very rare. Microscopically, a mixed inflammatory reaction is seen with clusters of polymorphonuclear leukocytes and noncaseating granulomas with epithelioid histiocytes and foreign body type giant cells.<sup>15</sup> The Diagnosis is usually made on identification of the fungus in a tissue biopsy or cytological smear of infected body fluid. The organism appears as round yeast cell which divides by broad based budding. The confirmation of diagnosis is through culture of the fungus. Treatment is based on the severity of disease. Itraconazole is used for mild to moderate cases.

Amphotericin B is used for severe meningeal lesions and immunocompromised patients.<sup>16</sup>

## Histoplasmosis

Histoplasmosis is caused by *Histoplasma capsulatum*, a dimorphic fungus found in soil. The disease spreads through inhaled spores. Disseminated histoplasmosis can be seen in immunocompromised conditions. Fever, dyspnoea, productive cough and anterior chest discomfort is seen in case of acute pulmonary infection. Granuloma formation and coagulative necrosis may result in cavitation of lung tissues. Fibrosis occurs due to healing of the granulomatous lesions. Oral involvement is usually secondary to pulmonary involvement. Oral lesions appear as papule, nodule, vegetation or an ulcer. Cervical lymph nodes are enlarged and firm. In HIV cases, ulcers with indurated border can be seen on the gingiva, palate or tongue. Investigations include culture of infective tissue on dextrose agar and biopsy. Microscopically small, oval yeasts with macrophages and reticulo-endothelial cells can be seen along with chronic granulomas with epithelioid cells, giant cells and caseous necrosis. Ketoconazole, Itraconazole and Amphotericin B are used for treatment of the infection.<sup>17,18</sup>

## Mucormycosis

Mucormycosis is also known as Phycomycosis or Zygomycosis. It generally occurs in individuals with decreased host response. The fungus invades arteries and causes damage secondary to thrombosis and ischaemia. The symptoms include ptosis, fever, swelling of cheek, and paresthesia. Oral manifestations include ulceration of palate that may be large and deep causing denudation of underlying bone. Ulcers can also occur in the lips, gingiva and alveolar ridge. This is a chronic granulomatous infection that shows multiple granulomatous areas having lymphocytes, giant cells and epithelioid cells.<sup>19</sup> Broad thin walled non-septate fungal hyphae with branching at right angles are seen in the connective tissue and confirmed by by Periodic acid Schiff stain. Treatment options include a combination of surgical debridement and systemic administration of Amphotericin B.<sup>20</sup>

## Rhinosporidiosis

Rhinosporidiosis, is a chronic granulomatous disease that usually presents as a polypoidal mass in the nasal cavity and nasopharynx. It is caused by *Rhinosporidium seeberi*.<sup>21</sup> It predominantly affects the mucus membranes of nose and nasopharynx. It also involves lips, palate, uvula, maxillary antrum, conjunctiva, lacrimal sac, epiglottis, larynx, trachea, bronchus, ear, scalp, skin, penis, vulva, and vagina. Rhinosporidiosis of the parotid duct manifests itself as a facial swelling. Microscopically, the organisms appear as sporangia containing large numbers of round or ovoid endospores. The connective tissue surrounding it shows granulation tissue and mixed inflammatory cells including lymphocytes, plasma cells, focal collection of histiocytes, and also neutrophils. Pseudocystic abscess formation, granulomatous reaction and fibrosis may also be seen.<sup>22</sup> Treatment options include complete excision with wide surgical margins, antifungal agents such as

griseofulvin and amphotericin B and treatment with dapsone.<sup>23</sup>

## Oral Myiasis

Oral myiasis is caused by infestation of tissue by larvae of houseflies and it is rare as the oral cavity does not provide the necessary habitat conducive for a larval lifecycle. Maggot infestations can occur in humans in two ways - by direct inoculation into wounds or by ingestion of infected materials like meat. Conditions leading to persistent mouth opening, accompanied with poor hygiene, suppurative lesions, severe halitosis, and facial trauma predispose the patient to oral myiasis. The growth of the larvae causes progressive destruction and cavitation. Finally a fibrous capsule is formed to which the larva firmly adheres, causing difficulty in dissection during surgery.<sup>24,25</sup> The dead larva may elicit an inflammatory response, with the formation of a foreign-body granuloma and, eventually, progression to calcification.<sup>27</sup> Diagnosis is generally made by the presence of larvae. The management of oral myiasis includes mechanical removal of the larvae, multivitamin tablets and antibiotics for secondary bacterial infections.<sup>26</sup>

## Toxoplasmosis

Toxoplasmosis is caused by *Toxoplasma gondii*. The disease is devastating for developing fetus (Congenital toxoplasmosis) or immunocompromised patient (AIDS, Transplant, cancer patients). It spreads from cat feces. Patients are usually asymptomatic. Low grade fever, cervical lymphadenopathy, fatigue, muscle or joint pain (few weeks to few months), necrotising encephalitis, pneumonia, myositis can also be present. Lymphadenopathy, involves one or more of lymph nodes in the para-oral region, such as buccal lymph node. The Histopathology shows characteristic reactive germinal centers and accumulation of eosinophilic macrophages. The diagnosis is through the serum antibody titres of *T.gondii* and biopsy of involved node. The treatment options for Immunocompromised patients include Sulfadiazine, clindamycin and pyrimethamine.<sup>29</sup>

## Foreign Body Granulomas

Foreign body granulomas are caused by Exogenous materials like silica, beryllium, glass, talc, or endogenous agents like hair, keratin, amyloid. In oral cavity gingiva is the most common site. Localised or diffuse erythema or ulcerations are seen. The condition does not resolve with improvement of oral hygiene. The biopsy generally shows granulomas and foreign body giant cells in absence of microorganisms. The management involves excision of the offending agent and involved tissue.<sup>30</sup> The term pulse granuloma (PG) has been applied to the foreign body reaction to vegetable material (leguminous crops, such as peas, beans, and lentils). It is a granulomatous response. It can occur either centrally or peripherally in the oral cavity. It is usually seen in the periapical or the sulcus area. Occasionally, the lesions may occur in the wall of the inflammatory odontogenic cysts.<sup>31</sup>

## Sarcoidosis

Sarcoidosis is a multisystem granulomatous disease of unknown etiology. It is characterized by the formation of uniform discrete, non caseating epithelioid granulomas. Two clinical syndromes - Lofgren Syndrome and Heerfordt Syndrome are associated with it. The possible etiologies include Infective and non-infective agents, Mycobacterium, propionibacterium and HHV-8. It is most commonly seen in young adults or in the middle aged. The Lungs (Hilar lymphadenopathy, Pulmonary infiltration), skin, lymph nodes, salivary glands, liver, spleen and bones are involved. Clinical features include malaise, cough, cutaneous lesions like multiple, raised red patches. Oral manifestations include small papules, nodules, plaques or submucosal masses, with bleb-like appearance containing clear yellowish fluid. The common sites in the oral cavity include buccal mucosa, gingiva, lips, floor of the mouth, tongue and palate. Bilateral involvement of the major salivary glands is seen. The diagnosis is based on the clinical, radiographic, histopathological, and non caseating epithelioid granulomas. Chest radiographs show bilateral hilar lymphadenopathy and diffuse parenchymal infiltrates. Increased serum ACE level is present. Kveim test and biopsy aid in confirmative diagnosis.<sup>10,29</sup>

## Crohn's Disease

Crohn's disease is a chronic Granulomatous disorder involving any portion of the GIT including the oral cavity. The oral lesions have predilection for the labial and buccal mucosa, and the mucobuccal folds. They are generally multifocal, linear, nodular, polypoid or diffuse mucosal thickenings. The ulcers are typically persistent, linear and deep and may cause pain. Subepithelial, noncaseating granulomatous inflammation characterized by epithelioid histiocytes, giant cells and lymphocytes can be seen microscopically. Topical corticosteroid therapy or intralesional corticosteroid injections may relieve the oral lesions.<sup>32</sup>

## Necrotizing Sialometaplasia

Necrotizing sialometaplasia is a self-limited, benign lesion of both major and minor salivary glands. It is most commonly seen in the hard palate. The underlying pathophysiology includes ischemia and infarct of mucosal salivary gland tissue that results in a self-healing inflammatory process. The predisposing factors include traumatic injuries, such as dental injection, blunt force trauma, denture wear etc. The histologic stages in the development and evolution of necrotizing sialometaplasia are - infarction, sequestration, ulceration, repair, and healing. Crateriform ulcers can be seen in the palate that can cause erosion of the palatal bone. It may be mistaken for malignancies, such as mucoepidermoid carcinoma, and invasive squamous cell carcinoma. Histopathological features include pseudoepitheliomatous hyperplasia, squamous metaplasia of the ducts and acini, preservation of the lobular architecture, lobular infarction with or without mucin spillage and inflammation secondary to the extravasation of mucin. Necrotising metaplasias resolve spontaneously within weeks.<sup>33,34</sup>



## Histiocytosis X

Histiocytosis X is also known as Langerhans cell histiocytosis. It is classified into two variations: localized or disseminated. Its types include Eosinophilic Granuloma, Hand-Schuller-Christian Disease, Letterer-Siwe Disease. It usually occurs in children under 15 years of age. The common signs include lymphadenopathy, fever, irritability, anorexia, pallor, middle ear otitis and anemia. When the jaws are affected, radiographs show well circumscribed, osteolytic lesions with the pathognomonic –floating teeth. Oral ulcerations, swellings, gingival inflammation, tooth mobility and loss are common. It can resolve spontaneously or it can disseminate, compromising visceral organs, with a fatal outcome.<sup>35</sup> Microscopically, it consists of sheets of polygonal histiocytes (Langerhans' cells) with some eosinophil, plasma cells, and lymphocytes. Histiocytes contain cytoplasmic inclusions known as X bodies. Electron microscopy reveals the characteristic Birbeck granules in the lesional cells. The disease is managed by surgical intervention, radiotherapy and chemotherapy.<sup>36</sup>

## Midline Lethal Granuloma

"Lethal midline granuloma syndrome" has been divided into the following clinical entities: Idiopathic midline destructive disease, Wegener's granulomatosis, polymorphic reticulosis and Non-Hodgkins lymphoma.<sup>37</sup> The idiopathic midline destructive disease is an unusual condition that resembles necrotic granulomas macroscopically and causes idiopathic progressive destruction of the nose, paranasal sinuses, palate, face and pharynx. The person affected typically appears to exhibit lack of resistance to insidious progress of the disease. Nasal stuffiness with or without nasal discharge is the major symptom. It begins as an oral or nasal ulcer and the ulceration eventually spreads. Perforation of the palate and nasal septum with mutilation of the surrounding tissues eventually occurs. Microscopically, extensive necrosis with inflammatory cell infiltration and new capillary formation can be seen. The disease is generally fatal. Chemotherapy with involved field external radiation is beneficial.<sup>38</sup>

## Wegener's Granulomatosis

Wegener's granulomatosis is a systemic autoimmune granulomatous disease. Pathogenesis includes abnormal immune reaction, secondary to a non-specific infection, hypersensitivity reaction to unknown antigen and possible hereditary predisposition. It consists of necrotizing granulomatous inflammation involving upper respiratory tract, Necrotizing glomerulonephritis and Systemic vasculitis involving small to medium sized vessels.<sup>28</sup> Malaise, fever, night sweats, oral ulcerations are common symptoms. Strawberry gingivitis, Gingival ulcerations, enlargements, bone loss, tooth mobility, palatal ulcerations, spontaneous exfoliation of teeth and failure of tooth socket to heal are the oral manifestations. Histopathologically, pseudo epithelial hyperplasia, subepithelial abscess and non-specific granulomatous lesion with scattered giant cells are seen. Clinical, laboratory and radiographic investigations must be done to rule out any underlying local or systemic disease.

Oral foci of infection should be identified and treated. Intralesional corticosteroids or systemic corticosteroids are used for treatment.<sup>39</sup>

## Melkersson-Rosenthal Syndrome

Orofacial granulomatosis is an entity that describes oral lesions with noncaseating granulomas. The Melkersson-Rosenthal syndrome has the elements of orofacial granulomatosis. It is a rare disorder and has an unknown etiology. It is characterized by a triad of orofacial swelling (recurrent), facial paralysis (relapsing), and fissured tongue. 'Meischer cheilitis' is the term used when granulomatous changes are confined to the lips (monosymptomatic form of Melkerson Rosenthal Syndrome). Episodic with swelling and enlargement of one or both lips is seen. Firm edema of the face may be present. Soft, firm or nodular lesion or fissured, reddish-brown, swollen, nonpruritic lips may be present.<sup>40</sup> Facial Palsy is intermittent at first, but later becomes permanent. It can be Unilateral or bilateral, partial or complete. Microscopically, epithelioid non-caseous granulomas, edema and perivascular lymphocytic infiltrates are seen.<sup>41</sup> Treatment options include intralesional corticosteroids, nonsteroidal anti-inflammatory agents, mast cell stabilizers, clofazimine, tetracycline, surgery and radiation.

## Conclusion

Granulomatous diseases of the oro-facial region can be caused by diverse immunologic, idiopathic, neoplastic, infectious, and fungal processes. They can cause a wide range of signs and symptoms in the head and neck region and also throughout the body. It poses a diagnostic dilemma for the clinician. It is therefore, essential to find the etiology and to recognize the granulomatous pattern in a biopsy specimen. Special stains like Ziehl-Neelsen stain, Gomori's Methenamine silver, PAS, Fite Faraco should be done whenever required. The correlation of histopathology with polymerase chain reaction (PCR) serological tests and culture, would further aid in recognizing the specific etiology. Thus, a thorough history and a complete physical examination, along with radiological, histological and laboratory evaluation may be required for the correct identification of the granulomatous disease for its specific treatment.

## References

1. Textbook of Pathology by Harsh Mohan, 7th edition.
2. Walter & Israel General Pathology, 7th Edition.
3. Williams CT., Granulomatous inflammation – a Review: J Clin Pathol; 1983;36; 723-733.
4. Kauzman, Orofacial Granulomatosis: 2 Case Reports and Literature, J Can Dent Assoc 2006; 72(4):325-9.
5. Review Swati Gotmare et al Granulomatous Diseases of the Oral tissues- A etiology & Histopathology, Scientific Journal Vol. I – 2007.
6. Jain P, Jain I. Oral Manifestations of Tuberculosis: Step towards Early Diagnosis. Journal of Clinical and Diagnostic Research: JCDR. 2014;8(12):ZE18-ZE21.
7. R. A. G. Khammissa, N. H. Wood, R. Meyerov, J. Lemmer, E. J. Raubenheimer, and Liviu Feller, "Primary Oral Tuberculosis as an Indicator of HIV Infection," Pathology Research International, vol. 2011, Article ID 893295, 4 pages, 2011.
8. Cotran RS, Kumar V., Robbins S. : Robbins pathologic basis of diseases: 5th ed.

9. Color Atlas of pathology – Pathologic principles Associated Disease sequel.
10. Prerna Pratik et al. Granulomatous Diseases Affecting Oral Cavity: A Review IJPCBS2014, 4(4), 849-855.
11. Fucci da Costa AP, Augusto da Costa Ner y J, Wan-del-Rey de Oliveira ML, Cuzzi T, Ramos-e-Silva M. Oral lesions in leprosy. Indian J Dermatol Venereol Leprol 2003;69:381-5.
12. Miller M., Haddad AJ., Review article; Cervicofacial Actinomycosis; Oral Surg. Oral Med. Oral Pathol. Oral Radio endol: 1998; 85: 496-508.
13. Laura W. Lamps, and Margie A. Scott Cat-Scratch Disease - Historic, Clinical, and Pathologic Perspectives (2004) American Journal of Clinical Pathology, 121, S71-S80.
14. Leão Jair Carneiro, Gueiros Luiz Alcino, Porter Stephen R.. Oral manifestations of syphilis. Clinics. 2006 Apr; 61(2): 161-166.
15. Saccente M, Woods GL. Clinical and Laboratory Update on Blastomycosis. Clinical Microbiology Reviews. 2010;23(2):367-381.
16. Kruse et al. Primary blastomycosis of oral cavity. J Craniofac Surg. 2010 Jan;21(1):121-3.
17. Patil K, Mahima VG, Prathibha Rani RM. Oral histoplasmosis. Journal of Indian Society of Periodontology. 2009;13(3):157-159.
18. Vidyanath S, Shameena P, Sudha S, Nair RG. Disseminated histoplasmosis with oral and cutaneous manifestations. Journal of Oral and Maxillofacial Pathology :JOMFP. 2013;17(1):139-142.
19. Sreenath G, Prakash AR, Kanth MR, Reddy PS, Vidhyadhari P. Rhinomaxillary Mucormycosis with Palatal Perforation: A Case Report. Journal of Clinical and Diagnostic Research: JCDR. 2014;8(9):ZD01-ZD03.
20. Deepa A, Nair BJ, Sivakumar T, Joseph AP. Uncommon opportunistic fungal infections of oral cavity: A review. Journal of Oral and Maxillofacial Pathology: JOMFP. 2014;18(2):235-243.
21. Rath R, Baig SA, Debata T. Rhinosporidiosis presenting as an oropharyngeal mass: A clinical predicament? Journal of Natural Science, Biology, and Medicine. 2015;6(1):241-245.
22. Arseculeratne SN. Recent advances in rhinosporidiosis and rhinosporidiumseeberix. Indian J Med Microbiol. 2002;20:119-31.
23. Rameshkumar A et al Rhinosporidiosis Presenting as a Facial Swelling: A Case Report ,Journal of International Oral Health 2015; 7(2):58-60.
24. Kumar SL, Manuel S, John TV, Sivan MP. Extensive gingival myiasis - Diagnosis, treatment, and prevention. Journal of Oral and Maxillofacial Pathology: JOMFP. 2011;15(3):340-343.
25. Reddy MHR, Das N, Vivekananda MR. Oral myiasis in children. Contemporary Clinical Dentistry. 2012;3(Suppl1):S19-S22.
26. Sankari LS, Ramakrishnan K. Oral myiasis caused by Chrysomya bezziana. Journal of Oral and Maxillofacial Pathology: JOMFP. 2010;14(1):16-18.
27. Fabio Francesconi and Omar Lupi. Myiasis. Clin. Microbiol. Rev. January 2012 vol. 25 no. 1 79-105.
28. D Geraint James .A clinicopathological classification of granulomatous disorders. Postgrad Med J 2000;76:457-465 doi:10.1136/pmj.76.898.457.
29. Shigeyuki Asano. Granulomatous Lymphadenitis. J Clin Exp Hematopathol 52(1) : 1-16, 2012.
30. Jham et al. Granulomatous foreign-body reaction involving oral and perioral tissues after injection of biomaterials: a series of 7 cases and review of the literature. J Oral Maxillofac Surg. 2009 Feb;67(2):280-5.
31. Acharya S, Hallikeri K, Anehosur V, Okade A. Oral pulse or hyaline ring granuloma: A case report and a brief review. Journal of Indian Society of Periodontology. 2015;19(3):327-332.
32. Daley TD, Armstrong JE. Oral manifestations of gastrointestinal diseases. Canadian Journal of Gastroenterology. 2007;21(4):241-244.
33. Madala et al. Necrotizing Sialometaplasia: A Diagnostic Dilemma, OHDM - Vol. 13 - No. 3 - September, 2014.
34. Diane L. Carlson, MD , Necrotizing Sialometaplasia - A Practical Approach to the Diagnosis Arch Pathol Lab Med – Vol 133, May 2009.
35. Martínez DSM et al. Oral manifestations of Langerhans cell histiocytosis (LHC): Review of scientific literature and case report, Revista Odontológica Mexicana 2012;16 (2): 123-130.
36. Madrigal-Martínez-Pereda C, Guerrero-Rodríguez V, Guisado-Moya B, Meniz-García C. Langerhans cell histiocytosis: Literature review and descriptive analysis of oral manifestations. Med Oral Patol Oral Cir Bucal. 2009 May 1;14 (5):E222-8.
37. Batra P, Shah N, Mathur S. Midline lethal granuloma: A clinical enigma. Indian J Dent Res. 2003;14:174-83.
38. Mallya V, Singh A, Pahwa M. Lethal midline granuloma. Indian Dermatol Online J 2013;4:37-9.
39. Siar et al, Strawberry Gingivitis As The First Presenting Sign Of Wegener's Granulomatosis: Report Of A Case, Eur J Med Res (2011) 16: 331-334.
40. Rogers RS. Melkersson-Rosenthal syndrome and orofacial granulomatosis. Dermatol Clin. 1996 Apr;14(2):371-9.
41. Kaminagakura E, Jorge J Jr. Melkersson Rosenthal syndrome: a histopathologic mystery and dermatologic challenge. J Cutan Pathol. 2011 Feb;38(2):241-5.



# Myofibroblasts in Oral Health and Disease

R.P. Srikanth<sup>1</sup>, K.Rajkumar<sup>2</sup>, T. Dinesh Kumar<sup>3</sup>, Ramya<sup>4</sup>, P. Jayashiri<sup>5</sup>

1,5 Post Graduate Student,

2 Head of Department

3,4 Reader

Department of Oral Pathology,  
SRM Dental College & Hospital,  
Ramapuram,  
Chennai

Received : 01.09.2015

Review Completed : 25.09.2015

Accepted : 10.10.2015

## ABSTRACT

Myofibroblasts (MFs) are the cells that are not only essential for the integrity of the human body by virtue of its role in physiological tissue repair (wound-healing), but can also threaten it by its ability to promote tumour development. Under physiological conditions, after wound healing, MFs disappear by apoptosis, but when there is continued insult, these myofibroblasts persist in the tissue and result in dysfunctional repair mechanisms causing excessive secretion of extracellular matrix with resultant fibrosis and scarring. Myofibroblasts are phenotypically altered fibroblasts and are a unique group of smooth-muscle like fibroblasts that have a similar appearance and function regardless of their tissue of residence. Myofibroblasts originate from different precursor cells, the major contribution being from local recruitment of connective tissue fibroblasts. However, local mesenchymal stem cells, bone marrow-derived mesenchymal stem cells and cells derived from an epithelial-mesenchymal transition process, may represent alternative sources of myofibroblasts when local fibroblasts are not able to satisfy the requirement for these cells during repair.

Apart from pathological remodelling of tissues, they play an important role in organogenesis and oncogenesis, inflammation, repair, and fibrosis. Because of their ubiquitous presence in all tissues, MFs play important roles in various organ diseases and perhaps in multisystem diseases as well. In the light of such severe consequences of MF appearance and dysfunction, the necessity of more profoundly understanding the molecular mechanisms of MF formation and function is essential. This paper highlights the overview of myofibroblasts, and their role in health and disease particularly in relation to diseases of oral cavity.

## Introduction

Myofibroblasts, by simple definition, are specialised fibroblasts, with smooth like features characterised by presence of contractile apparatus.<sup>1</sup> They are unique cells and are essential for the integrity of the mammalian body by virtue of its role in wound healing, but it can also threaten it by its ability to promote tumor development. Through the secretion of inflammatory and anti inflammatory cytokines, chemokines, growth factors, as well as extra cellular matrix proteins and proteases, they play an important role in organogenesis and oncogenesis, inflammation, repair and fibrosis in most organs and tissues. It is an almost universal cellular component in mammalian lesions, but not a typical component of normal untraumatised tissues.

The concept of Collagen, being the main element responsible for contraction of wound, changed in 1950. It was discovered that specialised fibroblasts were present in the granulation tissues. Microscopic studies revealed that these specialised cells are similar to that of smooth muscle cells which are capable of contraction. Later these smooth muscle like cells are termed as Myofibroblasts, by Gabbiani in 1971.<sup>2</sup>

Partly because of its absence in normal tissues, it has not been a part of conventional histologic teaching and has contributed difficulties in explaining the nature of these ubiquitous cells and in defining it. This article reviews on some important hallmarks related to its structure, immunophenotypes, origin and fate, its role in normal and in pathologic situations.

## Structure

Myofibroblasts have several unique morphological characteristics, few of which are present in fibroblast as well as smooth muscle cells. They are spindle shaped cells (Fig 1) with numerous cytoplasmic extensions containing actin microfilaments called as stress fibres and they are connected to each other by adherens and gap junctions and are connected to extracellular matrix by a transmembrane complex known as fibronexus.<sup>3</sup>

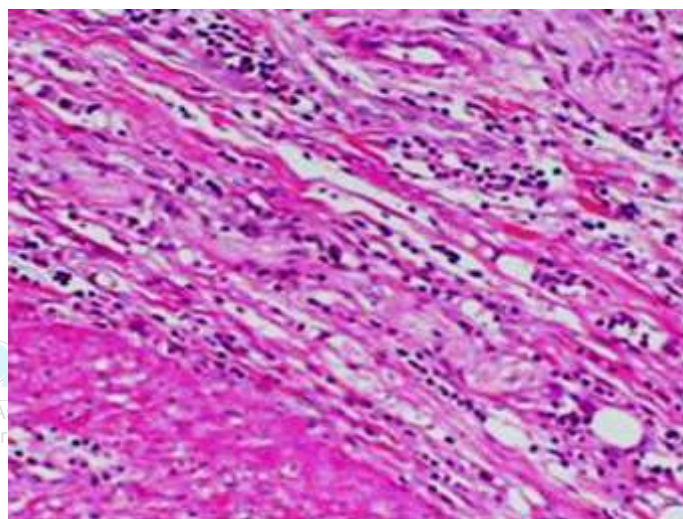


Fig 1: Myofibroblasts in stromal cells (Courtesy: Yuhiko Fuyuhiko, Masakazu Yashiro, Satoru Noda, Shinichiro Kashiwagi, Junko Matsuoka, Yosuke Doi, Yukihiro Kato, Kazuya Muguruma, Tetsuji Sawada, Kosei Hirakawa.

Myofibroblasts are associated with the progression of scirrhous gastric carcinoma. *Journal of Experimental and Therapeutic Medicine*; July 2010, 547-551)

Transmission electron microscopy shows, the cell membranes displays numerous invaginations. The cytoplasm is rich in well developed RER, Golgi apparatus, mitochondria and intended nucleus. (Fig 2)

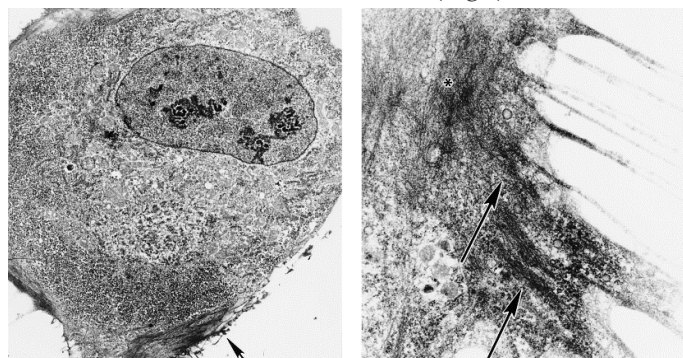


Fig 2: Transmission electron microscopy showing tubular epithelial-myofibroblast transdifferentiation (TEMt) (i) A cell in the early stage of transformation shows hypertrophy, an elongated morphology and a loss of apical polarity, microvilli and tight junctions.

There are prominent bundles of actin microfilament lying peripheral to the cytoplasm (arrow head) (ii) A cell at the late stage of transformation showing characteristic actin microfilaments bundles (arrows) throughout the cytoplasm. Magnification (i) x4200 (ii) 18,300

(Courtesy: Jun-Ming Fan, Yee-Yung Ng, Prudence A Hill, David J Nikolic-Paterson, Wei Mu, Robert C Atkins and Hui Y Lan. Transforming growth factor- $\beta$  regulates tubular epithelial-myofibroblast transdifferentiation in vitro. *Journal of international society of Nephrology* (1996) 56, 1455 – 1467)

Since, Myofibroblasts share features with fibroblasts (RER and Golgi apparatus) and with smooth muscle cells (myofilaments), it is seen that MF's are devoid of lamina – a structure seen in smooth muscle cells.

Further,  $\alpha$ -smooth muscle actin ( $\alpha$ -SMA) is present in others cells other than myofibroblasts like pericytes, endothelial cells, myoepithelium and pathological epithelia and one should not rely only on expression of  $\alpha$ -SMA alone in identification or in distinguishing myofibroblasts. So, electron microscopy plays an important role in distinguishing myofibroblasts from other cells.

### Immunophenotypes

Almost all myofibroblasts express  $\alpha$ -SMA, an actin isoform present in most of the types of smooth muscle cells. It is considered to be the main IHC marker in identifying myofibroblasts.<sup>4</sup>

Apart from  $\alpha$ -SMA, they also express desmin, myosin and vimentin. (Fig 3) Based on these expressions, myofibroblasts disclose five immunophenotypes: a) phenotype V, cells expressing vimentin alone; b) phenotype VA, those expressing vimentin and  $\alpha$ -SMA; c) phenotype VD, those expressing vimentin and desmin; d) phenotype VAD, those expressing vimentin,  $\alpha$ -SMA and desmin and e) phenotype VAM, those cells expressing vimentin,  $\alpha$ -SMA and myosin.

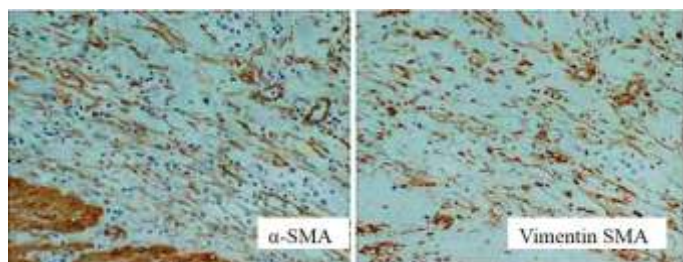


Fig 3: Myofibroblasts expression in stromal cells (Courtesy: Yuhiko Fuyuhiko, Masakazu Yashiro, Satoru Noda, Shinichiro Kashiwagi, Junko Matsuoka, Yosuke Doi, Yukihiko Kato, Kazuya Muguruma, Tetsuji Sawada, Kosei Hirakawa. Myofibroblasts are associated with the progression of scirrhous gastric carcinoma. *Journal of Experimental and Therapeutic Medicine*; July 2010, 547-551)

### Origin, differentiation of myofibroblast

Their occurrence in various physiological and pathological situations, makes it difficult to think about its exact source of origin. It is uncertain that the origin of myofibroblast is from the progenitor stem cells (possibly neuroepithelial stem cells), from the neural crest or simply trans-differentiate from the resident tissue fibroblasts or from tissue smooth muscle cells.<sup>5</sup>

In normal conditions, fibroblastic cells exhibit few or no actin associated cell to cell and cell to matrix contacts and little ECM production.<sup>6</sup>

After tissue injury, they become activated to migrate into the damaged tissue and to synthesize ECM components<sup>7</sup> by cytokines locally released from the inflammatory and resident cells<sup>8</sup>. Another important stimulus for this transition is the change of the mechanical microenvironment. In response to these mechanical challenge, fibroblasts gain contractile stress fibers that are composed of cytoplasmic actins,<sup>6</sup> hallmarking them as "Protomyfibroblasts".

The term protomyfibroblast are termed for those fibroblasts with stress fibers that do not express  $\alpha$ -SMA. For the transformation of protomyfibroblasts into mature myofibroblasts, mechanical stresses along with certain cytokines are necessary.

### Cytokines necessary for myofibroblast differentiation

Various cytokines and growth factors have a roles in myofibroblast differentiation<sup>8</sup>. Among these, especially, the transforming growth factor (TGF)  $\beta$ 1, (Fig 4) is the major growth factor and a potent inducer of myofibroblastic differentiation<sup>9</sup>.

Platelet derived growth factors (PDGF) plays an important role in the differentiation of fibroblasts into protomyfibroblasts<sup>10</sup>. TGF  $\beta$ 1 and ED – A FN (a variant of fibronectin) are key players in differentiation of protomyfibroblasts into mature myofibroblasts. Other factors like Granulocyte-macrophage colony stimulating factor (GM-CSF) and integrins also play a role.<sup>10</sup>

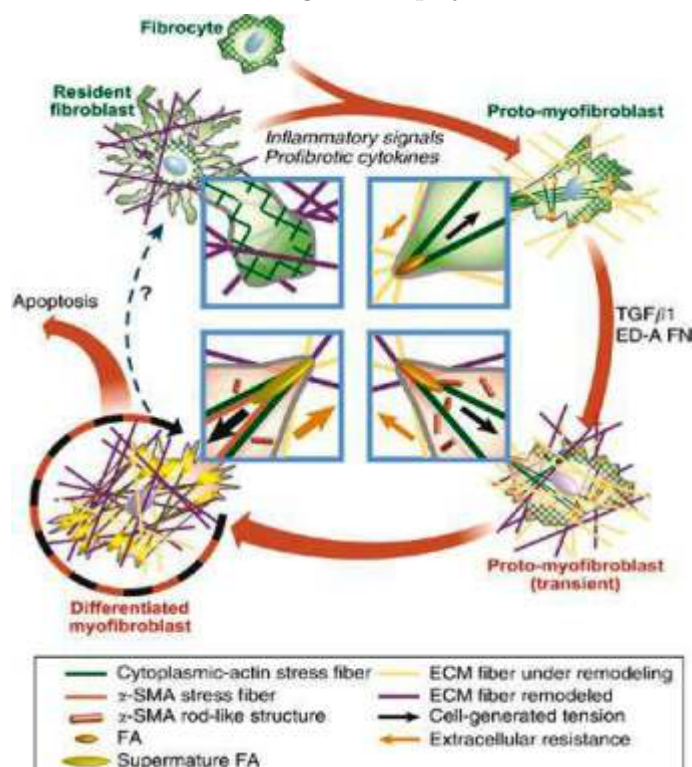


Fig 4: Differentiation of fibroblast into Myofibroblast. (Courtesy: Hinz Boris. Formation and Function of the Myofibroblast during Tissue Repair. *J Invest Derm.* 2007;127:526-537)



## Myofibroblasts in physiological situations

### Morphogenesis and organogenesis

Through epithelial-mesenchymal interactions, myofibroblasts are the main components of morphogenesis and organogenesis.<sup>5</sup> They do so by the discharge of soluble mediators of inflammation and growth factors and expression of their receptors and by the production of interstitial matrix and molecules of basement membrane.<sup>5</sup>

### Normal wound healing and wound contraction

Immediately after injury, the healing process allowing to restoration of the injured tissue occurs. According to the morphological changes in the course of the healing process, there occurs three phases of events described as a) Inflammatory phase, b) proliferative phase, for the development of granulation tissue and c) regenerative phase for maturation, scar formation and reepithelialisation<sup>11</sup>.

Myofibroblasts appear to be key cells in the process of wound healing and are found more numerous in the exudates layer of granulation tissue. Prostaglandins synthesized by these cells promote healing by restoration of the epithelium. Contraction of wound is because of the presence of  $\alpha$ -SMA filaments in the cytoplasm of these cells.<sup>12</sup>

The ECM, which is a mixture of collagen and ground substances and enzymes like matrix metalloproteinases (MMP's), required for tissue remodelling are also secreted by these cells.

So, they play a key role in the wound healing, seemingly as an addition to their function in normal growth and differentiation.<sup>5</sup>

## Myofibroblasts in pathological situations

### Role in inflammatory conditions

Myofibroblasts have an important position in the inflammatory response.<sup>5</sup> They produce both cytokines and chemokines and are capable of augmenting or down regulating the inflammatory response by the secretion of soluble mediators of inflammation. They also synthesise prostaglandins, expressing both COX-1 and the inducible COX-2 protein. On activation, myofibroblasts also express molecules for adhesion like intracellular adhesion molecule-1, vascular adhesion molecule and neural cell adhesion molecule. Thus lymphocytes, mast cells and neutrophils may dock on the myofibroblasts and participate in organised immunological and inflammatory reactions.

Ultrastructural study of various lesions of the oral cavity like giant cell fibroma<sup>13</sup> and Phenytoin induced gingival hyperplasia<sup>14</sup> revealed cells with numerous intracytoplasmic myofilaments with electron dense bodies similar to smooth muscle cells and fibroblasts and these cells are referred to as myofibroblasts.

## Myofibroblasts in Odontogenic cysts and tumors

Presence of myofibroblasts has been reported in the stroma of odontogenic cysts and tumors. Electron microscopic studies have demonstrated the presence of myofibroblasts in the stromal component of ameloblastoma (Fig 5e and f) and has been proposed that the presence of these cells could contribute to its aggressive behaviour<sup>15</sup>.

Various studies have been conducted on odontogenic cysts and tumors and has revealed that myofibroblasts were particularly more in lesions with locally aggressive behaviour like odontogenic keratocyst and solid variant of ameloblastoma.<sup>16</sup>

Studies conducted using IHC to demonstrate  $\alpha$ -SMA in odontogenic cysts reported that a variable proportion of the cyst wall fibroblasts showed expression for  $\alpha$ -SMA. The results of these study demonstrated that myofibroblasts contribute to cyst wall elasticity and also helps in cyst wall expansion.<sup>17</sup>

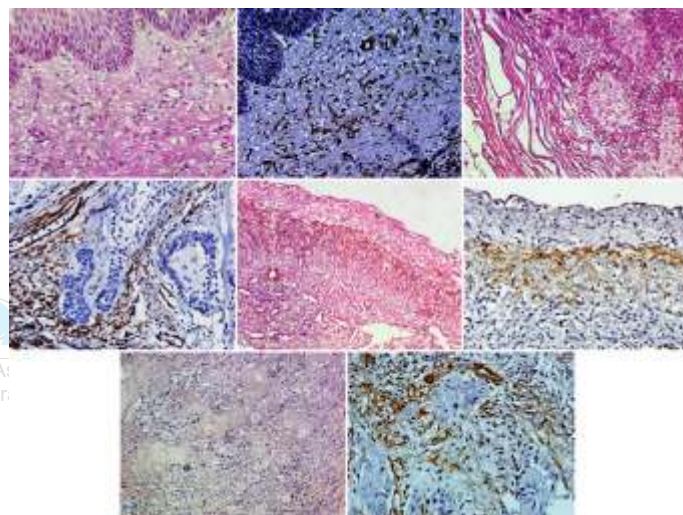


Fig 5(a) Odontogenic keratocyst (OKC) showing cystic lining epithelium and connective tissue capsule (H&E stain, ×400). (b) Photomicrograph showing  $\alpha$ -SMA positive myofibroblasts in the cyst wall of OKC (IHC stain, ×400). (c) Follicular ameloblastoma showing odontogenic epithelial islands in connective tissue stroma (H&E stain, ×400). (d) Photomicrograph showing  $\alpha$ -SMA positive myofibroblasts around odontogenic epithelial islands in follicular ameloblastoma (IHC stain, ×400). (e) Luminal variant of unicystic ameloblastoma (H&E stain, ×200). (f) Photomicrograph showing  $\alpha$ -SMA positive myofibroblasts in unicystic ameloblastoma (IHC stain, ×400). (g) Malignant epithelial islands in well-differentiated oral squamous cell carcinoma (H&E stain, ×400). (h) Photomicrograph showing  $\alpha$ -SMA positive myofibroblasts around tumor islands in oral squamous cell carcinoma (IHC stain, ×400)

(Courtesy Soujanya Piniseti, Ravikanth Manyam, Babburi Suresh, V Aparna: Myofibroblasts in oral lesions: A review. *Journal of Oral and Maxillofacial Pathology*, 2014 (18), 52- 57

## Myofibroblasts in Oral submucous fibrosis

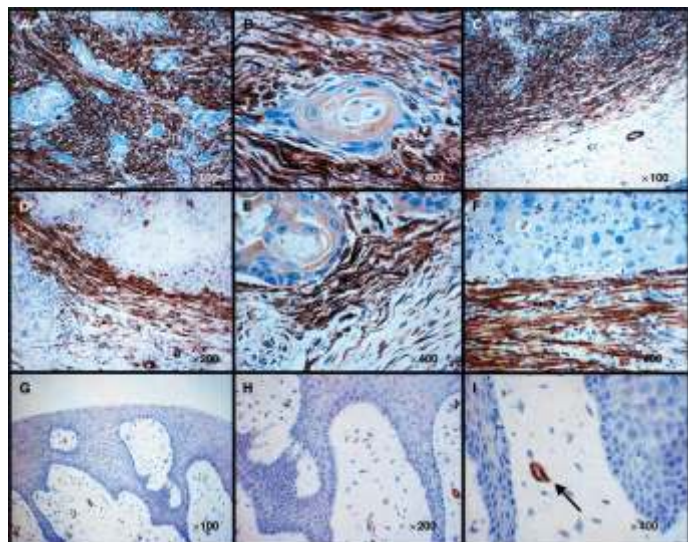
Pindborg in 1966 defined Oral submucous fibrosis (OSMF) as an insidious, chronic disease affecting any part of the oral cavity and sometimes the pharynx.

It is a potential malignant disorder characterised by inflammation and progressive submucous fibrosis. Myofibroblasts are considered to be the key cellular mediator in many fibrotic disorders promoting fibrosis. Studies have been done to identify the presence of myofibroblasts in OSMF and also have revealed that there

is a significant increase in the number of myofibroblasts between early and advanced stages of OSMF. It is also suggested that these cells can also be used as a marker for evaluating the severity of the condition.<sup>18</sup>

## Myofibroblasts in Oral cancer

It is a well known fact that many epithelial tumors are characterised by local accumulation of connective tissue cells and extracellular material. This phenomenon is known as stromal reaction.<sup>19</sup> One of the stromal reaction is the appearance of specialised fibroblasts called Myofibroblasts. Myofibroblasts interact with epithelial cells and other connective cells and may thus control tumor invasion and angiogenesis.<sup>20</sup> Trans-differentiation of fibroblasts into myofibroblasts is a crucial step in tumorigenesis, which is mediated by the growth factors and cytokines secreted by the tumor cells. These myofibroblasts in turn secrete numerous growth factors and inflammatory cytokines that stimulate epithelial cell proliferation. These cells also act along with the immune system and promote angiogenesis, basement membrane degradation, invasion and metastasis.<sup>21-23</sup>



**Fig 6: Stroma of oral SCC contains prominent myofibroblasts in vivo.** Immunohistochemistry showing SMA expression by myofibroblasts in oral SCC and lack of expression in benign fibroepithelial hyperplasia. (A) Islands of SCC scattered throughout a myofibroblastic stroma with prominent SMA expression (magnification= x100). (B) A single island of SCC surrounded by SMA-positive myofibroblasts (magnification= x400). (C) Smooth muscle actin expression is concentrated at the tumour margin. Strong SMA expression by myofibroblasts is only detected in the near vicinity of the tumour. Consequently, the margin of the carcinoma appears sharply defined where it abuts 'normal' fibroblastic tissue (magnification= x100). (D-F) Strong induction of SMA expression immediately adjacent to islands of SCC (magnification= x200, x400, x400, respectively). This was usually seen adjacent to the invasive margin at the tumour periphery. (G-I) Lack of SMA expression in fibroblasts of benign fibroepithelial hyperplasia (magnification= x100, x200, x400, respectively). The arrow in (I) indicates positive SMA staining of smooth muscle in the wall of a blood vessel, which serves as an internal positive control.

(Courtesy: M P Lewis, K A Lygoe, M L Nystrom, W P Anderson, P M Speight, J F Marshall and G J Thomas. Tumour-derived TGF- $\beta$ 1 modulates myofibroblast differentiation and promotes HGF/SF-dependent invasion of squamous carcinoma cells. *British Journal of Cancer* (2004) 90, 822-832.

## Conclusion

Myofibroblasts are ubiquitous cells with similar properties and functions that play significant roles in morphogenesis, organogenesis, and wound healing as well as in disease. As they are present in virtually all tissues, it is possible that they may play a role in multisystem diseases. Understanding the role of the stromal cells and ECM will allow us to identify more precise prognostic markers and potential device new therapeutic options and prevent various diseases caused by these miraculous multipotential cells. Studies can help us to use only beneficial effects of myofibroblasts and control their activation wherever they act hyperactive.

## References

- Tomasek JJ, Gabbiani G, Hinz B, Chaponnier C, Brown RA. Myofibroblasts and mechano-regulation of connective tissue remodelling. *Nat Rev Mol Cell Biol* 2002;3:349-63.
- Gabbiani G, van G B & Majno G. Presence of modified fibroblasts in granulation tissue and their possible role in wound contraction. *Experientia* 27:549-50, 1971.
- Hinz B, Gabbiani G. Cell-matrix and cell-cell contacts of myofibroblasts: Role in connective tissue remodelling. *Thromb Haemostasis* 2003;90:993-1002
- Vered M, Shohat I, Buchner A, Dayan D. Myofibroblasts in the stroma of odontogenic cysts and tumors can contribute to variations in the biologic behaviour of lesions. *Oral Oncol* 2005;41:1028-33.
- Powell DW, Mifflin RC, Valentich JD, Crowe SE, Saada JI, West AB. Myofibroblasts. I. Paracrine cells important in health and disease. *Am J Physiol* 1999;277(1 Pt 1):C1-9
- Tomasek JJ, Gabbiani G, Hinz B, Chaponnier C, Brown RA: Myofibroblasts and mechano-regulation of connective tissue remodeling. *Nat Rev Mol Cell Biol* 2002, 3:349-363
- Hinz B: Formation and function of the myofibroblast during tissue repair. *J Invest Dermatol* 2007, 127:526-537
- Werner S, Grose R: Regulation of wound healing by growth factors and cytokines. *Physiol Rev* 2003, 83:835-870
- Desmouliere A, Geinoz A, Gabbiani F, Gabbiani G: Transforming growth factor-beta 1 induces alpha-smooth muscle actin expression in granulation tissue myofibroblasts and in quiescent and growing cultured fibroblasts. *J Cell Biol* 1993, 122:103-111.
- Van Beurden HE, Von den Hoff JW, Torensma R, Maltha JC, Kuijpers-Jagtman AM. Myofibroblasts in Palatal Wound Healing: Prospects for the Reduction of Wound Contraction after Cleft Palate Repair. *J Dent Res* 2005;84(10):871-80.
- Gurtner GC, Werner S, Barrandon Y, Longaker MT: Wound repair and regeneration. *Nature* 2008, 453:314-321.
- Soujanya Piniseti, Ravikanth Manyam, Babburi Suresh, V Aparna: Myofibroblasts in oral lesions: A review. *Journal of Oral and Maxillofacial Pathology*, 2014 (18), 52-57
- Weathers DR, Campbell WD. Ultrastructure of the giant-cell fibroma of the oral mucosa. *Oral Surg Oral Med Oral Pathol* 1974;38:550-61.
- Dill RE, Iacopino AM. Myofibroblasts in phenytoin-induced hyperplastic connective tissue in the rat and in human gingival overgrowth. *J Periodontol* 1997;68:375-80.
- Rothhouse LS, Majack RA, Fay JT. An ameloblastoma with myofibroblasts and intracellular septate junctions. *Cancer* 1980;45:2858-63.
- Mashhadiabbas F, Moghadam SA, Moshref M, Elahi M. Immunohistochemical detection and ultrastructure of myofibroblasts in the stroma of odontogenic cysts and ameloblastoma. *Iranian Red Crescent Med J* 2010;12:453-7.
- Lombardi T, Morgan PR. Immunohistochemical characterization of odontogenic cysts with mesenchymal and myofilaments markers. *J Oral Pathol Med* 1995;24:170-6.
- Angadi PV, Kale AD, Hallikerimath S. Evaluation of myofibroblasts in oral submucous fibrosis: Correlation with disease severity. *J Oral Pathol Med* 2011;40:208-13.
- Pallavi D, Shirol, Dayaanand D. Shirol. Myofibroblasts in Health and Disease. *International Journal of Oral and Maxillofacial Pathology*. 2012; 3(1): 23-27
- Gabbiani G. The Evolution of the Myofibroblast Concept: a Key Cell for Wound Healing and fibrotic diseases. *G Gerontol* 2004;52:280-2.
- Desmouliere A, Guyot C, Gabbiani G. The stroma reaction of myofibroblast: A key player in the control of tumor cell behavior. *Int J Dev Biol* 2004;48:505-17.
- Etamad-Moghadam S, Khalili M, Tirgary F, Alaeddini M. Evaluation of Myofibroblasts in oral epithelial dysplasia and squamous cell carcinoma. *J Oral Pathol Med* 2009;38:639-43.
- Zidar N, Gale N, Kambic V, Fischinger J. Proliferation of myofibroblasts in the stroma of epithelial hyperplastic lesions and squamous carcinoma of the larynx. *Oncology* 2002;62:381-5.



# Low intensity pulsed ultrasound in periodontal regeneration

S.Gopalakrishnan<sup>1</sup>, Parthiban Saket<sup>2</sup>, V.Shankarram<sup>3</sup>

1 Reader,

2 Senior lecturer,

3 Professor,

Thai Moogambigai Dental College and Hospital,

Mugappair, Chennai

Received : 31.08.2015

Review Completed : 28.09.2015

Accepted : 05.10.2015

## Introduction

Dental caries and periodontal diseases are the two most diseases of the oral cavity. Not only do they present physical and social hazards but also seriously compromise human health and quality of life. Tissue engineering has contributed to the cessation of many oral diseases. Several methods have been described to enhance cellular performance and low intensity pulsed ultrasound (LIPUS) has shown to play an important role in cell metabolism. LIPUS stimulation is a classical therapeutic modality for bone regeneration and its efficiency has been widely reported over the years. Interestingly, recent studies have provided evidence that LIPUS plays an important role in the metabolism of periodontal cells and tissues as well.

## Lipus and Biologic Mechanisms

Normal bone physiology is known to be regulated by mechanical stimulation. Both osteoblastic and osteoclastic activity have been proved to be mediated by mechanical stimuli<sup>1</sup>. Osteoclasts initiate bone resorption in response to determined signals and osteoblasts are recruited to deposit bone matrix in response to a coupling signal. Osteoclast and osteoblast activity could thus be related to opposite strain modalities. During orthodontic tooth movement, for example, the networked reactions that occur in and around periodontal ligament and alveolar bone cells change compressive and tensile stresses into molecular events, resulting in bone resorption and formation, respectively<sup>2</sup>. Other types of mechanical stimulation could thus modify cell metabolism, including ultrasound. LIPUS (intensity ranging from 30 - 100 mW/cm<sup>2</sup>) is an acoustic radiation that can be transmitted into the living tissues as pressure waves resulting in biochemical events at the cellular level<sup>3</sup>. LIPUS has been shown to stimulate bone and cartilage cells in vitro, indicating that ultrasound exerts direct anabolic effects such as production of growth factors and other signaling molecules, osteogenic differentiation and extra cellular matrix production<sup>4</sup>. The mechanisms involved in LIPUS-stimulated tissue repair is by the anabolic biophysical effects caused by mechanical stress and fluid micro-streaming which has an impact on the cellular plasma membrane. This triggers a cascade of intracellular

signal transduction which in turn causes a subsequent gene transcription<sup>5</sup>.

## Lipus and Bone Regeneration

Mechanical stimulus to bone is of a great importance for maintaining the bone mass and structural stability of the skeleton. When bone is mechanically loaded, movement of fluid within the spaces surrounding bone cells generates a disparity in fluid levels. This in turn stimulates osteoclasts and osteoblasts, resulting in an enhanced anabolic activity for bone remodeling. Bone repair and regeneration, accelerated bone fracture healing, and an enhanced osteogenesis at the distraction site have been demonstrated during invivo studies with the use of Therapeutic LIPUS<sup>6</sup>. LIPUS stimulation has also been shown to enhance expression of bone formation-related genes such as collagen type I and X, aggrecan, transforming growth factor beta, runt related gene-2, osteocalcin<sup>7</sup>, insulin-like growth factor-I, bone sialoprotein and alkaline phosphatase. In addition, LIPUS has been reported to promote protein synthesis and calcium uptake in various osteoblastic cell lines<sup>8</sup>. The enhancement of COX-2 gene expression and synthesis of endogenous prostaglandin E2 (PGE2) plays an important role in bone remodeling<sup>9</sup>.

## Lipus and Periodontal Ligament Regeneration

Periodontal ligament is subjected to various kinds of mechanical stress during every stage of cell proliferation and differentiation<sup>10</sup>. In a previous study, cyclic stretch stimulation mediated periodontal ligament cells differentiation, thus regulating the function of the periodontal ligament as a source of cementoblasts and osteoblasts through the EGF/EGF-R system<sup>11</sup>. It has been reported that LIPUS is effective in releasing fibroblast growth factors from a macrophage like cell line<sup>12</sup> and also helps in inducing early cementoblastic differentiation from the periodontal ligament by promoting the formation of substrate and increasing alkaline phosphatase (ALP) activity, and also enables the regeneration of periodontal tissue destroyed by periodontal disease and repair of root resorption<sup>13</sup>. Mostafa et al. (2009) demonstrated that ALP and OPN expressions were also induced in human gingival fibroblasts treated with LIPUS helping in osteogenic potential differentiation<sup>14</sup>.

## Lipus and Cementum Regeneration

Cementum is a thin mineralized tissue covering the tooth root surface and assists in anchoring teeth to surrounding alveolar bone, maintaining the structural stability and physiological function of the dentition<sup>15</sup>. A certain degree of root resorption occurs in most treatment cases, ranging from just a slight apical resorption to a complete tooth root loss<sup>16</sup>. The cementum layer covering the root surface plays a

crucial role in preventing resorption during tooth movement. Cementoblasts share many characteristics with osteoblasts, including similar molecular properties and the ability to promote mineralization. Studies have shown that cementum metabolism is also controlled by mechanical stimulus similar to bone. It has been reported that mechanical loading enhances the expression of phenotypic makers such as OCN and BSP in cementoblast however, the expression was just moderately stimulated compared to osteoblasts<sup>17</sup>. El-Bially et al. (2004) have published studies showing that LIPUS prevented root resorption during experimental tooth movement in humans<sup>18</sup>. Studies also have showed that LIPUS up-regulated the expression of several genes related to mineral metabolism in mouse cementoblasts<sup>19</sup>. LIPUS stimulation also significantly up-regulates COX-2 mRNA expression and enhanced PGE2 production inducing cementoblastic differentiation and matrix mineralization through EP2/EP4 prostaglandin receptors pathway<sup>20</sup>. Furthermore, assessment was done to see the inhibitory effect of LIPUS application on root resorption using an experimental model of tooth replantation involving luxation and immediate replacement of maxillary first molars in rats<sup>21</sup>. The results evidenced that the area of root resorption lacunae was statistically decreased in LIPUS treated sample. In addition, some in vitro studies have shown that LIPUS may contribute to the reduction of the trauma-induced inflammatory reaction through impairment of the TNF- $\alpha$  signaling pathway, suggesting its potential as a therapeutic tool to optimize the regenerative potential of periodontal tissues on replanted teeth<sup>22</sup>.

### Lipus and Gingival Regeneration

LIPUS application in implant dentistry have reported accelerated soft-tissue healing as well as osseointegration. In addition, it was suggested that the ultrasound treated wounds were at a more advanced stage in the repair process<sup>12</sup>. The cellular mechanisms underlying LIPUS induced tissue regeneration was done and studies by Ikai et al. (2008) showed that a daily LIPUS treatment protocol of 20 minutes for a period of 4 weeks has a beneficial effect on gingival epithelium cells, accelerating periodontal wound healing after flap surgery<sup>8</sup>. In other study using gingival epithelial cells, Shiraishi et al (2011) reported that LIPUS accelerates soft-tissue healing by increasing the expression of connective tissue growth factor (CCN2/CTGF), an important gene for wound healing and angiogenesis in periodontal tissues<sup>9</sup>.

### Lipus and Implant Osseointegration

The use of endosseous dental implants for replacing missing teeth increased considerable over the last few years and may be considered as the current most popular treatment option for edentulous patients. LIPUS helps in enhancement of endogenous bone healing around biomaterials through different forms of biophysical stimulations<sup>23</sup>. A study done by Tanzer et al. (1996) showed that LIPUS enhanced the rate and extent of bone growth into fully porous coated implants inserted into dog femora<sup>24</sup>. Studies done by Hsu et al. (2011) showed that ultrasound stimulation helps in good blood flow and

mature type I collagen fibers around titanium implants, and accelerated bone formation. In addition, pulsed ultrasound effectively promotes cell migration and new bone regeneration in tissue culture of MG63 osteoblast like cells<sup>25</sup>. Studies done by Ustun et al. (2008) showed that LIPUS stimulation increases the area, bone volume and bone implant contact ratio values in tibial bone suggesting that LIPUS application may accelerate and promote bone healing around dental implants leading to a higher quality and faster osseointegration<sup>26</sup>.

### Lipus and Gene Delivery

Periodontal disease or inflammatory root resorption is relevant pathologic condition that can lead to tooth loss. In this regard, several tissue-engineering techniques have been proposed to restore periodontal integrity<sup>27</sup>. Administration of growth factors has proved to exert positive effect with some clinical limitations such as proteolytic degradation, rapid diffusion, and solubility of the delivery vehicle<sup>28</sup>. In order to optimize the results, gene transfer methods were introduced with limitation of progress in clinical periodontal gene therapy by the immunogenicity and cytotoxicity of viral vectors and low transfection efficiency with regard to non-viral vectors<sup>29</sup>. Therapeutic ultrasound associated to echo contrast agents such as nano/ microbubbles can optimize gene transfection in vitro and in vivo<sup>30</sup>. Recently, it has been shown that therapeutic ultrasound also provides an effective gene delivery system for bone and periodontal regeneration<sup>31</sup>. Studies done by Watanuki et al. (2009) showed that LIPUS stimulation in mouse calf muscles injected with BMP-4 plasmids and transcuteaneous electroporated showed increased ectopic calcium and total collagen content and bone area<sup>32</sup>.

### Discussion

Among the causes of teeth loss, inflammatory root resorption has received a great concern due to its unpredictability, difficult control and lack of biological understanding. The resorption of hard tissue in primary teeth is a normal physiologic phenomenon. On the other hand, the hard tissues of permanent teeth are not resorbed under healthy conditions and the resorption is thus considered a pathologic process<sup>33</sup>. Different causes have been attributed to the root resorption process including pressure, inflammation, neoplastic process and systemic conditions<sup>34</sup>. The major problem encountered after tooth replantation and orthodontic tooth movement is the resorption of root. Approaches aiming to inhibit root resorption and restore periodontal integrity during the dental practice are still the subject of debate and investigation. Some therapeutic approaches have been proposed to inhibit root resorption after tooth replantation and can induce periodontal regeneration<sup>35</sup>. In this context, non-invasive modality such as LIPUS therapy has been given increased attention and risen as promising therapeutic tool for the regeneration of periodontium. The effectiveness of LIPUS for bone regeneration is already universally accepted and some recent papers have provided evidence that it can exert beneficial effects in other kinds of tissues, including teeth. In addition, LIPUS

presents low toxicity, low immunogenicity, non-invasiveness, highly targeted selectivity, and repeated applicability. However, the diversity of techniques, application protocols and ultrasound specifications found in the literature may cause confusion for the clinician. Bains et al. (2008) have pointed out that ultrasound application in both diagnosis and periodontal therapy seems to present promising results; however, long-term evidence-based studies are required to use ultrasound in routine periodontal practice<sup>36</sup>.

## Conclusion

Despite LIPUS therapy has been widely used in the fields of orthopedic surgery and rehabilitation, its availability by dental professionals is still incipient. The effects of LIPUS in bony tissue seem to be well understood, but the literature has still lacked for available information about its effects on periodontal tissues. The present review brings out current evidence that LIPUS has a positive effect on tooth and periodontal cells metabolism, suggesting that LIPUS can be a promising therapeutic tool for the regeneration of tooth support tissues.

## References

- Petrtyl M, Hert J, Fiala P. Spatial organization of the haversian bone in man. *J Biomech* 1996; 29: 1619.
- Tan SD, Xie R, Klein-Nulend J, Van Rheden RE, Bronckers AL, Kujipers-Jagtman AM, Van den Hoff JW, Maltha JC. Orthodontic force stimulates eNOS and iNOS in rat osteocytes. *J Dent Res* 2009; 88: 255-60.
- Buckley MJ, Banes AJ, Levin LG, et al. Osteoblasts increase their rate of division and align in response to cyclic mechanical tension in vitro. *Bone Miner* 1998; 4: 225-36.
- Claes L, Willie B. The enhancement of bone regeneration by ultrasound. *Prog Biophys Mol Biol* 2007; 93: 384-98.
- Khan Y, Laurencin CT. Fracture repair with ultrasound: clinical and cell-based evaluation. *J Bone Joint Surg* 2008; 90: 138-44.
- Duarte LR. The stimulation of bone growth by ultrasound. *Arch Orthop Trauma Surg* 1983; 101: 153-9. [14] Dyson M. Therapeutic applications of ultrasound. In: Biological effects of ultrasound. Nyborg WL, Ziskin MC, Eds. Churchill Livingstone, New York, NY 1985; pp. 121-33.
- Chen YJ, Wang CJ, Yang KD, et al. Pertussis toxin-sensitive Gai protein and ERK dependent pathways mediate ultrasound promotion of osteogenic transcription in human osteoblasts. *FEBS Lett* 2003; 554: 154-8.
- Naruse K, Miyauchi A, Itoman M, Mikuni-Takagaki Y. Distinct anabolic response of osteoblasts to low-intensity pulsed ultrasound. *J Bone Miner Res* 2003; 18: 360-9.
- Kokubu T, Matsui N, Fujioka H, Tsunoda M, Mizuno K. Low intensity pulsed ultrasound exposure increases prostaglandin E2 production via the induction of cyclooxygenase-2 mRNA in mouse osteoblasts. *Biochem Biophys Res Commun* 1999; 256: 284-7.
- Bosshardt DD, Degen T, Lsng NP. Sequence of protein expression of bone sialoprotein and osteopontin at the developing interface between repair cementum and dentin in human deciduous teeth. *Cell Tissue Res* 2005; 320: 399-407.
- Matsuda N, Yokoyama K, Takeshita, S, Watanabe M. Role of epidermal growth factor and its receptor in mechanical stress-induced differentiation of human periodontal ligament cells in vitro. *Arch Oral Biol* 1998; 43: 987-97.
- Young SR, Dyson M. The effect of therapeutic ultrasound on angiogenesis. *Ultrasound Med Biol* 1990; 16: 261-9. 224 The Open Dentistry Journal, 2012, Volume 6 Braga Rego et al.
- Inubushi T, Tanaka E, Rego EB, et al. Effects of ultrasound on the proliferation and differentiation of cementoblast lineage cells. *J Periodontol* 2008; 79: 984-90.
- Mostafa NZ, Uludağ H, Dederich DN, Doschak MR, El-Bialy TH. Anabolic effects of low-intensity pulsed ultrasound on human gingival fibroblasts. *Arch Oral Biol* 2009; 54: 743-8.
- Ten Cate AR. The periodontium: Oral histology, development, structure and function. Mosby, St Louis, MO 2003; 276-9.
- Hollender L, Ronneman A, Thilander B. Root resorption, marginal bone support and clinical crown length in orthodontically treated patients. *Eur J Orthod* 1980; 2: 197-205.
- Pavlin D, Gluhak J. Effect of mechanical loading on periodontal cells. *Crit Rev Oral Biol Med* 2001; 12: 414-24.
- El-Bialy T, El-Shamy I, Graber TM. Repair of orthodontically induced root resorption by ultrasound in humans. *Am J Orthod Dentofacial Orthop* 2004; 126: 186-93.
- Dalla-Bona DA, Tanaka E, Oka H, et al. Effects of ultrasound on cementoblast metabolism in vitro. *Ultrasound Med Biol* 2006; 32: 943-8.
- Rego EB, Inubushi T, Kawazoe A, et al. Ultrasound stimulation induces PGE2 synthesis promoting cementoblastic differentiation through EP2/EP4 receptor pathway. *Ultrasound Med Biol* 2010; 36: 907-15.
- Rego EB, Inubushi T, Miyauchi M, et al. Ultrasound stimulation attenuates root resorption on rat replanted molars and impairs TNF- $\alpha$  signaling in vitro. *J Periodont Res* 2011; 46: 648-54.
- Brånemark PI, Zarb G, Albrektsson T. Tissue-integrated prosthesis. In: Brånemark PI, editor. Osseointegration in clinical dentistry. Chicago, IL: Quintessence Publishing Co; 1985; pp. 11-76.
- Fini M, Giavaresi G, Setti S, Martini L, Torricelli P, Giardino R. Current trends in the enhancement of biomaterial osteointegration: Biophysical stimulation. *Biomaterials* 2004; 27: 681-90.
- Tanzer M, Harvey E, Kay A, Morton P, Bobyn JD. Effect of non-invasive low intensity ultrasound on bone growth into porous-coated implants. *J Orthop Res* 1996; 14: 901-6.
- Hsu SK, Huang WT, Liu BS, Li SM, Chen HT, Chang CJ. Effects of near-field ultrasound stimulation on new bone formation and osseointegration of dental titanium implants in vitro and in vivo. *Ultrasound Med Biol* 2011; 37: 403-16.
- Ustun Y, Erdogan O, Kurkcü M, Akova T, Damlar I. Effects of low-intensity pulsed ultrasound on dental implant osseointegration: a preliminary report. *Eur J Dent* 2008; 2: 254-62.
- Ramseier CA, Abramson ZR, Jin Q, Giannobile WV. Gene therapeutics for periodontal regenerative medicine. *Dent Clin North Am* 2006; 50: 245-63.
- Pradeep AR, Karthikeyan BV. Tissue engineering: prospect for regenerating periodontal tissues. *Indian J Dent Res* 2003; 14: 224-9.
- Ramseier CA, Abramson ZR, Jin Q, Giannobile WV. Gene therapeutics for periodontal regenerative medicine. *Dent Clin North Am* 2006; 50: 245-63.
- Nishida K, Doita M, Takada T, et al. Sustained transgene expression in intervertebral disc cells in vivo mediated by microbubble-enhanced ultrasound gene therapy. *Spine* 2006; 31: 1415-9.
- Sheyn D, Kimelman-Bleich N, Pelled G, Zilberman Y, Gazit D, Gazit Z. Ultrasound-based nonviral gene delivery induces bone formation in vivo. *Gene Ther* 2008; 15: 257-66.
- Watanuki M, Kishimoto KN, Kotajima S, Iwabuchi S, Kokubun S. Effect of low-intensity pulsed ultrasound on scaffold-free ectopic bone formation in skeletal muscle. *Ups J Med Sci* 2009; 114: 242-8.
- Gunraj MN. Dental root resorption. *Oral Surg Oral Med Oral Pathol Oral Radiol Endod* 1999; 88: 647-53.
- Ravindran S, Chaudhary M, Tumsare M, Patil S, Wadhwan V. A Scanning electron microscopic study of the patterns of external root resorption under different conditions. *J Appl Oral Sci* 2009; 17: 481-6.
- Loberg EL, Engstrom H. Thyroid administration to reduce root resorption. *Angle Orthod* 1994; 64: 395-9.
- Bains VK, Mohan R, Bains R. Application of ultrasound in periodontics: Part II. *J Indian Soc Periodontol* 2008; 12: 55-61.



# Electrosurgery applications in dental practice

Dinesh CC<sup>1</sup>, Sri Vandana T<sup>2</sup>, Vamsi Lavu<sup>3</sup>, S K Balaji<sup>4</sup>

1,2 Tutor

Department of Community Dentistry

3,4 Associate Professor

Department of Periodontics,

Faculty of Dental Sciences,

Sri Ramachandra University

Received : 01.09.2015

Review Completed : 25.09.2015

Accepted : 30.09.2015

## Introduction

Electrosurgery is an extremely useful device which has wide applications in the performance of soft tissue dental procedures. As the name indicates, it involves the usage of electrical current which has been modified for use in dental soft tissue procedures. It provides very good hemostasis and hence is a good prospect for management of vascular lesions. The basic mechanism of action involves a conversion of electrical energy to thermal energy which produces the tissue changes observed.<sup>1</sup>

## Electrosurgical Principles

The electrosurgical principles are electrosection, electrocoagulation, electrodessication and electrofulguration. Of use in dental surgery are electrosection and electrocoagulation only. Electrosection involves a cutting of tissues with an electrode which is heated by an electrical current. Electrocoagulation involves achieving hemostasis by producing a large area of thermal burn and coagulating the blood/ vessel wall in the site of application. It is more useful for venous and capillary bleeding as compared to arterial pulsatile type of bleeding. Electrodessication and electrofulguration are not used in dentistry and involve tissue changes by surface heating/ drying of the tissues.<sup>2</sup>

Electrocautery uses low voltage, high amperage, current to heat a surgical tip to cause tissue dessication, coagulation or necrosis by direct transfer of heat to tissues. Two types of electrosurgical devices are available: monopolar and bipolar devices. In a monopolar device, the patient body serves to complete the circuit between the active electrode and the neutral plate, whereas in a bipolar device, the circuit is completed between the two electrodes within the confines of the handpiece, thereby reducing the possibility of accidental burns for the patient.<sup>3</sup>

## Electrosurgical Tip designs

The electrocautery device (Fig 1) has a variety of tips (made of fine tungsten) which fit into a handpiece and the cutting current and coagulation current can be modified depending on the nature of the lesion/ site being treated. The tip designs include needle / bent needle electrode, loop electrodes and ball / bar electrodes.

The needle and bent needle are used for cutting procedures, ball/ bar electrodes are meant for coagulation and loop (circular/ triangular) are meant for tissue contouring.<sup>4</sup> (Fig 2)

## Indications for use of electrosurgery in dental practice: [Used for soft tissue procedures only]<sup>5</sup>

1. Crown lengthening
2. Gingivectomy/ gingivoplasty
3. Operculectomy
4. Frenectomy
5. Excision of gingival epulis / vascular lesions / fibromas etc. (Fig 3)
6. De-pigmentation
7. Gingival troughing following crown preparation
8. Gingival polyp excision

## Limitations of electrosurgery

1. Contra-indicated in individuals with cardiac pace-makers.<sup>6</sup>
2. Necrosis of bone/ cementum can occur if prolonged contact of more than 10-15 seconds is maintained due to thermal damage.<sup>7</sup>
3. It has to be used with caution in sites with thin gingiva – high risk for gingival recession.<sup>7</sup>

Healing following treatment with electrosurgery is delayed if excessive charring happens during the procedure. In summary, the electrosurgery is a less known but useful tool for the management of common practice situations such as polyp excision / crown lengthening / gingival enlargement etc.

In summary, electrosurgery represents a handy tool for the dental practitioner and serves as a value addition in dental procedures. However, it should be used with caution due to its far reaching implications on the patient if not used correctly.

## References

1. Kurtzman GM, Silverstein LH. Diagnosis and treatment planning for predictable gingival correction of altered passive eruption. *Pract Proced Aesthet Dent*. 2008;20(2):103-8.
2. Goldstein BM. Demystifying electrosurgery. *Dent Today*. 2005;24(11):114-6.
3. Shuman IE. Bipolar versus monopolar electrosurgery: clinical applications. *Dent Today*. 2001;20(12):74-6, 78-81.
4. Louca C, Davies B. Electrosurgery in restorative Dentistry: 2. Clinical applications. *Dent Update*. 1992; 19(9):364-6.
5. Flocken JE. Electrosurgical management of soft tissues and restorative dentistry. *Dent Clin North Am*. 1980 Apr;24(2):247-69.
6. Roedig JJ, Shah J, Elayi CS, Miller CS. Interference of cardiac pacemaker and implantable cardioverter-defibrillator activity during electronic dental device use. *J Am Dent Assoc*. 2010;141(5):521-6.
7. Simon BI, Schuback P, Deasy MJ, Kelner RM. The destructive potential of electrosurgery on the periodontium. *J Periodontol*. 1976;47(6):342-7.

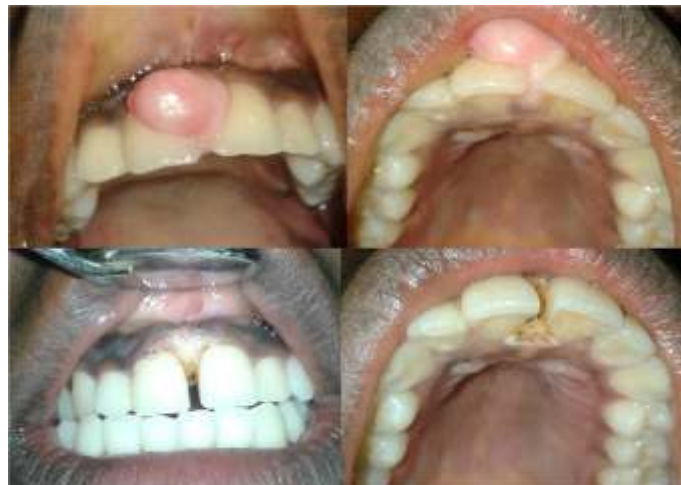

Fig 3: Sample case of excision of gingival epulis

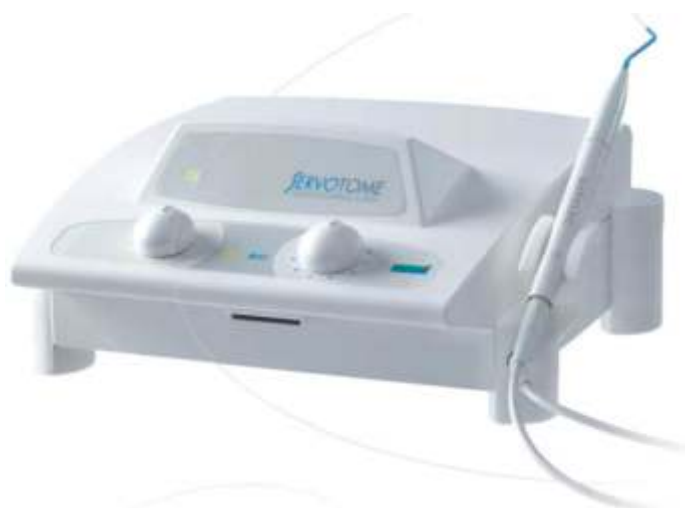

Fig 1: Satelec Servotome: Monopolar Electrosurgery device

ida  
Dental Association  
idras Branch

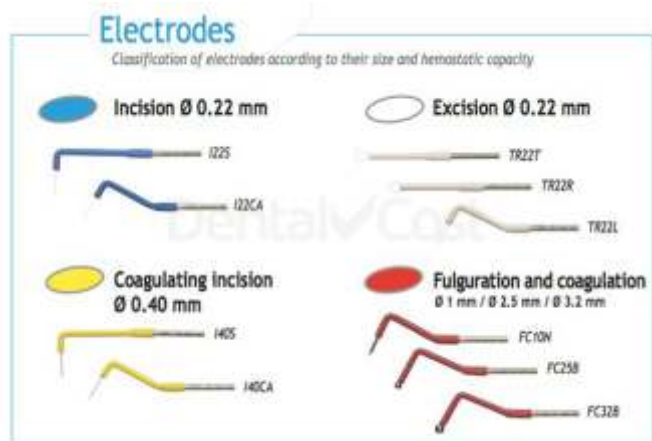


Fig 2: Electrosurgical tips with applications (Satelec)



# Herpes Virus 1 - A Hidden Culprit in Perimplant Mucositis - A Case Report

Dr. Parthiban Saket<sup>1</sup>, Dr. S.Gopalakrishnan<sup>2</sup>, Dr. V.Shankarram<sup>3</sup>

1 Senior lecturer,  
2 Reader,  
3 Professor,  
Thai Moogambigai Dental College  
& Hospital,  
Mugappair, Chennai - 600107.

Received : 31.08.2015  
Review Completed : 27.09.2015  
Accepted : 07.10.2015

## ABSTRACT

Herpes simplex virus-type 1 (HSV-1) causes oral infection in lip, tongue, buccal mucosa and alveolar mucosa and later it causes recurrent ulcers causing mucositis around tooth structure as well as around the prosthesis. This case report elaborates how HSV-1 may cause peri implant mucositis in a healthy implant site which was placed 5 years back. A 22-year-old female patient presented in a private dental hospital for the treatment of perimplantitis with chief complaint of marginal inflammation of the gingiva and vesicle formation accompanied by pain, fever, and regional lymphadenopathy. Patient was advised antibiotic and anti-inflammatory medications. Two weeks after medication, the patient returned complaining of increased severity of the symptoms with vesicle formation around her lips. Perimplant curettage was done with plastic curettes and patient advised oral hygiene instructions. A biopsy was taken for histological and direct immunofluorescence examinations, which revealed the presence of herpetic origin of the lesion following which acyclovir was prescribed. After 1 week of antiviral therapy, inflammation around the implant site and lips disappeared, and healthy soft tissue margin around implant was observed.

**KEYWORDS:** Herpes simplex virus, Perimplant Mucositis Histological and Immunofluorescence examination.

## Introduction

Herpes simplex viruses are the most ubiquitous form of viruses in the adult population. Highly virulent forms of the virus have been often been detected in the lips, tongue, buccal mucosa and alveolar mucosa causing recurrent oral infections. In alveolar mucosa it causes recurrent infection causing ulcer and vesicles around the soft tissue surrounding the tooth structure and prosthetic appliances<sup>1</sup>. Peri-implant diseases is a site-specific infectious disease that causes an inflammatory process in soft tissues, and bone loss around an osseointegrated implant prosthesis<sup>2</sup>. Peri-implant mucositis has been described as a disease in which the presence of inflammation is confined to the soft tissues surrounding a dental implant with no signs of loss of supporting bone<sup>3</sup>.

From a clinical standpoint, signs that determine the presence of peri-implant mucositis include bleeding on probing and/or suppuration, which are usually associated with probing depths more than 4 mm and no evidence of radiographic loss of bone beyond bone remodeling<sup>4</sup>. The description of the inflammatory process of periimplant mucositis around an implant is quite similar to gingivitis around natural teeth. Glycoproteins from saliva adhere to exposed titanium surfaces with concomitant microbiological colonization. Similar to bacterial colonization, herpetic infection can possibly occur on the implant region<sup>5</sup>. A case report of similar condition was seen where perimplant Mucositis affected with herpes infection was successfully treated after proper diagnosis.

## Case Report

A 22 Year old female patient presented herself in a private dental college for the treatment of inflammation around his previously placed implant. The patient reported of gingival recession with vesicle formation in her implant region which is placed 5 years back in her left upper lateral incisor region. The lesion was accompanied by pain, fever and regional lymphadenopathy and an unusual onset modality of perimplant mucositis and the associated symptoms led to suspect a likely viral etiology. Before the treatment of the perimplant mucositis the patient

underwent scaling and periodontal parameters were assessed including plaque index, bleeding index, bleeding on probing, pocket depth and clinical attachment level in 12 region<sup>6</sup>. Due to the unusual and rapid development of inflammation in implant region accompanied by pain, fever and regional lymphadenopathy the patient was put on screening for two weeks with oral antibiotics and the patient was instructed to report after two weeks. After two weeks the patient was examined and on oral examination, perimplant mucositis was similar in condition with increased suppuration with no plaque accumulation and patient developed vesicle formation in her lip region along with pain fever and persistent painful lymphadenopathy<sup>7</sup>. Patient was advised biopsy following which biopsy was taken by removing the lesional tissue around the implant. Cytologic smears also were taken from the epithelial surface and the specimens were delivered to the pathology department for histological and immunofluorescence examinations<sup>8</sup>. After removal of biopsy, the region was curetted with plastic curettes and oral hygiene instructions were given.

## Histopathological Evaluation

The histopathological examination showed an intra epithelial vesicle containing exudates, inflammatory and virus infected epithelial cells. The infected cells showed the typical effects of HSV-1 infection with an increase in the size of the nuclei and margination of chromatin. The cytologic smear showed the same cellular changes<sup>9</sup>. Identification of HSV-1 was done by direct immunofluorescence and cytologic smears using the (FITC) Fluorescein Isothiocyanate conjugated primary antibody to HSV-1<sup>10</sup>. The positivity of the smear was demonstrated by the yellow-green color which appeared with in the multinucleated epithelial cells<sup>11</sup>. A cytological specimen from normal mucosa was used as a normal control and a cytological specimen from a labial herpetic lesion as a positive control.

## Treatment

After the histopathological examination, Acyclovir was immediately prescribed at a dosage of 200mg 4 times daily for 7 days. One week later, the lesion had completely disappeared. During the following 6 months period, the patient was prescribed a meticulous program of supportive periodontal treatment to prevent recurrence of disease. A new prosthetic restoration with an esthetic supragingival margins was constructed as well. Professional prophylaxis was performed at 3 month intervals. During this time, the patient showed signs of good periodontal health with no signs of recurrent herpetic lesions in other areas too.

## Discussion

In this paper, a patient with HSV-1 induced periimplant mucositis in relation to left lateral incisors (as confirmed by histopathological and immunofluorescence examinations) revealing clinical characteristics different from those associated with typical periimplant mucositis reported. The onset and progression of this lesion were extremely dramatic, resulting in the rapid deterioration of the marginal gingiva in only a few days of time. Moreover, it was accompanied by other clinical signs and symptoms such as pain, fever, and regional lymphadenopathy. This gingival lesion was treated by means of mechanical debridement with plastic curettes and based on the definitive diagnosis of HSV-1 infection, acyclovir was prescribed, which was successful in treating the lesions.<sup>12</sup> The strict regimen of plaque control during supportive periodontal treatment was given and a new prosthesis was given. There was no marginal recession nor loss of gingiva occurring in the implant region or other regions in oral cavity later.

### Some conclusions may be drawn from this case report:

Periimplant Mucositis may be caused not only by bacterial infection or improper prosthesis or with poor oral hygiene, but also by HSV-1 infection.<sup>13</sup>

The clinical characteristics of HSV-1 causing periimplant Mucositis are different from those caused by normal etiologies. The sudden onset, rapid progression and dramatic destruction of the periimplant mucosal tissues associated with pain, fever, and lymphadenopathy are the primary characteristics features.<sup>14</sup>

Based on these differences, clinical diagnosis must be performed by the periodontist at an early stage.

Acyclovir made it possible to successfully treat recurrent viral gingival lesion in its early stage.<sup>15</sup>

Strict collaboration with the oral pathologist may be useful in detecting HSV-1 infection in its early stage.<sup>16</sup>

## Conclusion

HSV infection around implant region is a difficult diagnosis to establish. It should be considered in the differential diagnosis of any case of severe herpes infection with concomitant fever, pain and lymphadenopathy. Based on these clinical features, diagnosis of periimplantitis induced by HSV-1 must be carried out at an early stage to establish a successful therapy. If HSV infection is suspected, then therapy with acyclovir or vidarabine must

be rapidly initiated for a better chance of a favorable outcome.

## References

1. Intraoral Transmission and the Colonization of Oral Hard Surfaces M. Quirynen, W. Papaioannou and D. van Steenberghe Journal of Periodontology Oct 1996, Vol. 67, No. 10, Pages 986-993.
2. Mombelli A, Lang NP. The diagnosis and treatment of peri-implantitis. Periodontol 2000 1998;17:63-76.
3. Lindhe J, Meyle J. Peri-implant diseases: Consensus report of the Sixth European Workshop on Periodontology. J Clin Periodontol 2008;35(Suppl. 8):282-285.
4. Sanz M, Chapple IL. Clinical research on peri-implant diseases: Consensus report of Working Group 4. J Clin Periodontol 2012;39(Suppl. 12):202-206.
5. Al-Ahmad A, Wiedmann-Al-Ahmad M, Faust J, Bächle M, Follo M, Wolkewitz M, Hannig C, Hellwig E, Carvalho C, Kohal R. Biofilm formation and composition on different implant materials in vivo. Journal of Biomedical Materials Research. Part B, Applied Biomaterials. 2010;95:101-109.
6. Salvi GE, Aglietta M, Eick S, Sculean A, Lang NP, Ramseier CA. Reversibility of experimental peri-implant mucositis compared with experimental gingivitis in humans. Clin Oral Implants Res 2012;23:182-190.
7. Arduino PG, Porter SR. Oral and perioral herpes simplex virus type 1 (HSV-1) infection: review of its management. Oral Dis. May 2006;12(3):254-70.
8. Knight V, Brasier F, Greenberg SB, Jones DB Immunofluorescent diagnosis of acute viral infection See comment in PubMed Commons below South Med J. 1975 Jun;68(6):764-6.
9. Vidyanath S, Balan U, Ahmed S, Johns DA. Role of cytology in herpetic stomatitis. J Cytol [serial online] 2014 [cited 2014 Nov 13];31:122.
10. Powers CN. Diagnosis of infectious diseases: A cytopathologist's perspective. Clin Microbiol Rev 1998;11:341-65.
11. Gupta LK, Singhi M K. Tzanck smear: A useful diagnostic tool. Indian J Dermatol Venereol Leprol 2005;71:295-9
12. Prato GP, Rotundo R, Magnani C, Ficarra G, Viral etiology of gingival recession. A case report J Periodontol. 2002 Jan;73(1):110-4.
13. Pontoriero R, Tonetti MP, Carnevale G, Mombelli A, Nyman SR, Lang NP. Experimentally induced peri-implant mucositis. A clinical study in humans. Clin Oral Implants Res 1994;5:254-259.
14. Jankovic S, Aleksic Z, Dimitrijevic B, Lekovic V, Camargo P, Kenney B Prevalence of human cytomegalovirus Epstein-Barr virus HSV in subgingival plaque at peri-implantitis, mucositis and healthy sites. A pilot study. Int J Oral Maxillofac Surg. 2011 Mar;40(3):271-6. doi: 10.1016/j.ijom.2010.11.004. Epub 2010 Dec 8.
15. Rooney JF, Straus SE, Mannix ML, et al. Oral acyclovir to suppress frequently recurrent herpes labialis. A double-blind, placebo-controlled trial. Ann Intern Med. 1993;118(4):268-272.
16. Cernik C, Gallina K, Brodell RT. The treatment of herpes simplex infections: an evidence-based review. Arch Intern Med. 2008;168(11):1137-1144.

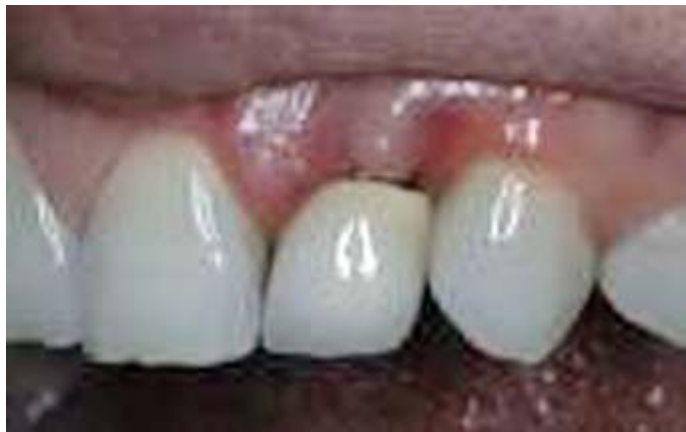

Fig 1: Infection and inflammation around the implant

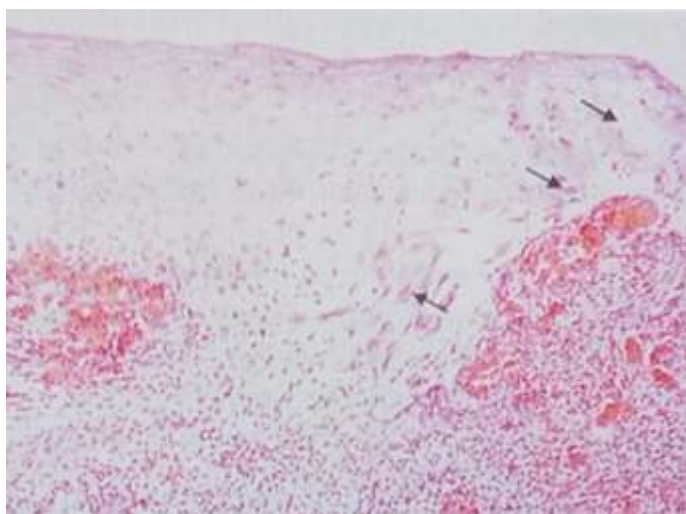


Fig 2: gingival biopsy reveals an intra epithelial vesicle with acantholysis and typical cytological features of HSV infection (arrows) (hematoxylin and eosin, original magnification 10)

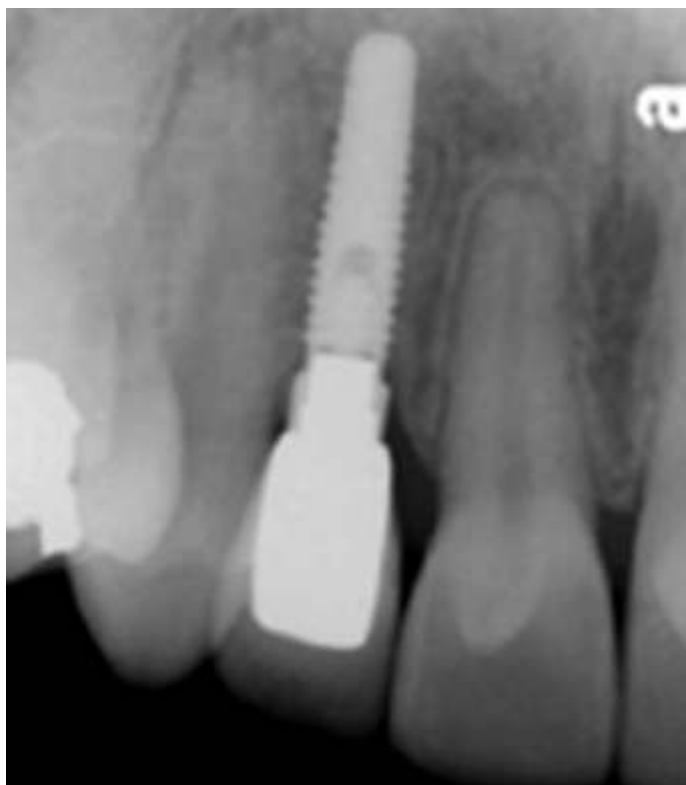

Fig 3: Radiographic picture of the patient

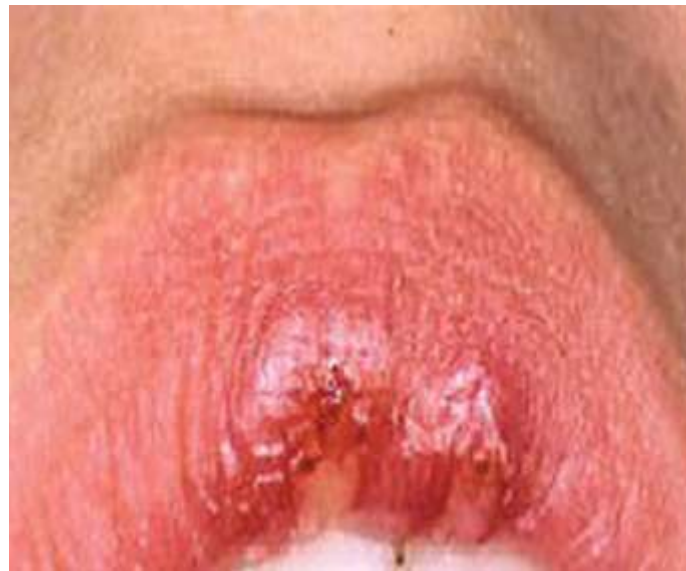

Fig 4: Vesicles present on the lips

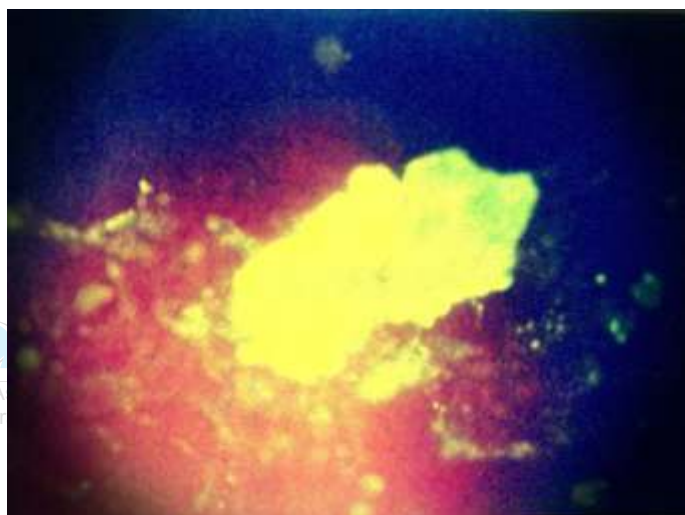

Fig 5: Direct immunofluorescence on cytologic smear shows HSV-1 positively revealed by the typical yellow green color of grouped cells (original magnification 10)

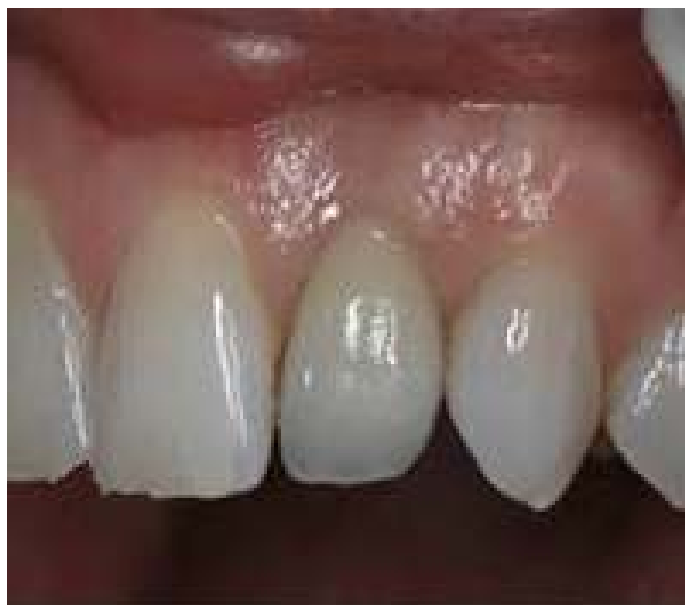

Fig 6: Postoperative clinical Picture of 12 region



# A review of Probiotics in treating oral microbial infections

Manikandan Kumaraswamy<sup>1</sup>, Ramalakshmi M<sup>2</sup>, Md. Abdul Rahim Akbar<sup>3</sup>

1 Associate Professor,  
Department of Prosthodontics,  
Thai Moogambigai Dental College & Hospital,  
2 Reader,  
Department of Oral medicine & Radiology,  
Madha Dental College & Hospital,  
3 Senior Lecturer,  
Department of Periodontology,  
RAGAS Dental College & Hospital

Received : 31.08.2015

Review Completed : 20.09.2015

Accepted : 25.09.2015

## ABSTRACT

Probiotics are live microorganisms thought to be beneficial to the host organism with proven health benefits. Traditionally, probiotics have been associated with gut health, and most clinical interest has been focused on their use for prevention or treatment of gastrointestinal infections and diseases. However during the last decade several investigators have also suggested the use of probiotics for oral health purposes. This article discusses about the significance of probiotic therapy as a means to fight common dental conditions.

**Keywords:** Probiotics, Oral health, Lactobacillus, Bifidobacterium

## Introduction

In recent years, with the threat of widespread antibiotic resistance rendering many antibiotics useless against important diseases, there is an increased necessity not only to minimise antibiotic use and develop novel non-antibiotic-based treatments, but also to raise the profile of disease prevention. There is a public appetite for new therapies that are perceived to be natural through, for example, manipulation of the resident microbiota by the ingestion of probiotic bacteria or prebiotics. There has been a shift away from treating dental diseases by targeting specific oral pathogens towards an ecological and microbial community-based approach to understand conditions, such as caries and periodontal diseases<sup>4</sup>. These approaches recognise the importance of maintaining the natural balance of the resident oral microbiota and the need to carefully modulate host immune responses to the microflora at a site.

## Probiotics

Etymologically, the term appears to be a composite of the Latin preposition pro ("for") and the Greek adjective (bios, "life")<sup>2</sup>. Probiotics are defined as viable micro-organisms that confer health benefit when administered in sufficient doses. According to the currently adopted definition by FAO/WHO, probiotics are: "Live microorganisms which when administered in adequate amounts confer a health benefit on the host"<sup>1</sup>. Lactic acid bacteria (LAB) and bifidobacteria are the most common types of microbes used as probiotics; certain yeasts and bacilli may also be helpful. Some streptococci, enterococci and commensal *Escherichia coli* have also been claimed to have beneficial effects. Probiotics are commonly consumed as part of fermented foods with specially added active live cultures; such as in yogurt, soy yogurt, or as dietary supplements.

## Oral Microbiota

Given the complexity of the oral microbiota; more than 700 species have been detected in the human mouth and the

resident microbiota of one individual may comprise 30 to >100 species. A wide variety of sites in the mouth are heavily colonised. Supragingival and subgingival plaque form through sequential and specific adhesive interactions that result in a complex climax community. The tongue is heavily colonised and micro-organisms on the dorsum of the tongue are reservoirs for supragingival and subgingival plaque and salivary microbial populations. Many oral bacteria, especially streptococci, also survive within buccal epithelial cells. The following species are listed as 'true' oral commensal micro-organisms: *Streptococcus mitis*, *Streptococcus oralis*, *Actinomyces naeslundii*, *Fusobacterium nucleatum*, *Haemophilus parainfluenzae*, *Eikenella corrodens* and some species of *Prevotella*. Other studies have generated an increasingly long list of culturable and unculturable bacteria with a significant association with healthy sites.

## Origin and Vehicles for Probiotic Delivery

Probiotic bacteria are natural inhabitants of the intestinal flora and the vast majority of the strains and species that are examined in research for their probiotic properties are isolated from healthy humans although there are some that originate from fermented food. The increasing interest for replacement therapy has, however, opened a market for other consumer products such as lozenges, sucking tablets and chewing gums.

Probiotics are provided into the food items in one of four basic ways:

1. As a culture concentrate added to beverages (e.g. fruit juice).
2. Inoculated into prebiotic fibres which promote the growth of probiotic bacteria.
3. Inoculated into milk and milk based foods (e.g. milk drinks, yoghurt, cheese, bio drinks).
4. As lyophilized, dried cells packaged as dietary supplements (tablets, chewing gums, straws).

The archetypical probiotic food is yoghurt and daily consumption of dairy products seems to be the most natural way to ingest probiotic bacteria. Another advantage is that milk products contain basic nutrients for the growing child; they are also considered safe for the teeth with possible beneficial effects on the salivary microbial composition and inhibition of caries development, due to their natural content of casein, calcium, and phosphorous. A formulation of approximately 108 probiotic bacteria per gram or millilitre with an intake of 1.5–2 dL per day is recommended and the dairy products should preferably be non-sweetened and contain only natural sugar.

### Dental Caries<sup>9,18,22,25,26</sup>

The advantage of incorporating probiotics into dairy products lies in their capacity to neutralize acidic conditions. For example, it has already been reported that cheese prevents demineralization of the enamel and promotes its remineralization. Comelli and colleagues reported that of 23 bacterial strains used in the dairy industry, *Streptococcus thermophilus* and *Lactobacillus lactis* ssp. *lactis* were the only ones with the capacity to integrate into a biofilm present on a hydroxyapatite surface and to interfere with development of the cariogenic species *Streptococcus sobrinus*. More recently, it was demonstrated that isolates of *W. cibaria* had the capacity to inhibit, both in vitro and in vivo, biofilm formation by *S. mutans* and to prevent proliferation of this bacterial strain.

In other studies, one strain of *L. rhamnosus* and the species *L. casei* inhibited in vitro growth of 2 important cariogenic streptococci, *S. mutans* and *S. sobrinus*. containing *S. thermophilus* and *L. bulgaricus* had selective bactericidal effects on streptococci of the mutans group. Several clinical studies have demonstrated that regular consumption of yogourt, milk or cheese containing probiotics led to a decrease in the number of cariogenic streptococci in the saliva and a reduction in dental plaque. More specifically, Nikawa and colleagues reported that consumption of yogourt containing *Lactobacillus reuteri* over a period of 2 weeks reduced the concentration of *S. mutans* in the saliva by up to 80%. Comparable results were obtained by incorporating probiotics into chewing gum or lozenges.

### Probiotics and Periodontal Disease<sup>9,22,25</sup>

Periodontal disease is classified into 2 types: gingivitis and periodontitis. Gingivitis is characterized by inflammation limited to the unattached gingiva, whereas periodontitis is a progressive, destructive disease that affects all supporting tissues of the teeth, including the alveolar bone. The main pathogenic agents associated with periodontitis are *P. gingivalis*, *Treponema denticola*, *Tannerella forsythia* and *Aggregatibacter actinomycetemcomitans*. These bacteria have a variety of virulent characteristics allowing them to colonize the subgingival sites, escape the host's defence system and cause tissue damage. The persistence of the host's immune response also constitutes a determining factor in progression of the disease.

In one recent study, the prevalence of lactobacilli, particularly *Lactobacillus gasseri* and *L. fermentum*, in the oral cavity was greater among healthy participants than among patients with chronic periodontitis. Various studies have reported the capacity of lactobacilli to inhibit the growth of periodontopathogens, including *P. gingivalis*, *Prevotella intermedia* and *A. actinomycetemcomitans*. Together, these observations suggest that lactobacilli residing in the oral cavity could play a role in the oral ecological balance.

### Oral Candida<sup>15</sup>

It has been suggested that oral Candida incidence increases with age (Lockhart et al., 1999), possibly because of impaired immunity. Several elements in the immune system, such as T- lymphocytes, granulocytes, NK-cells, mast cells, and macrophages, account for the protection against Candida infections (Peterson, 1992). *Lactobacillus* GG and *Propionibacterium* JS cause enhanced T-cell and B-cell proliferation in mice (Kirjavainen et al., 1999). Probiotics have also stimulated the production of IFN enhanced phagocytic capacity (Arunachalam et al., 2000), and increased the proportions of helper T-lymphocytes and the activity of natural killer cells in elderly patients (Gill et al., 2001). Probiotics may also inhibit the Candida growth by producing antimicrobial compounds (Ström et al., 2002; Strus et al., 2005), and may inhibit its adhesion to epithelial cells (Reid et al., 1995). In an in vitro model mimicking gastrointestinal conditions, *Lactobacillus* suppressed the growth of Candida after antibiotic treatment (Payne et al., 2003) possibly by competing for the same receptor sites.

They tested 4 denture cleaners - Dentural, Medical Interporous, Steradent Active Plus, and Boots Smile. They found that all of the denture cleansers were effective at both removing the yeast (*Candida albicans*) biofilm and disinfecting the denture but some biofilm still remained that led to regrowth. They noted that despite the soaking the dentures were recolonizing with the yeast biofilm. Therefore, as they put it, "alternative mechanical disruptive methods are required to enhance biofilm removal." So that means you need to brush the dentures as well as soak them to get the best result.

### Probiotics and Halitosis<sup>16,20,25</sup>

Halitosis (bad breath) is a discomfort rather a disease. Strains used as probiotic for mouth and gut associated halitosis include *E.coli* Nisle 1917, *S.salivarius* K12, three *Weissella confusa* isolates and a lactic acid forming bacterial mixture. The administration of bacteriocin producing *S.salivarius* after an oral antimicrobial mouthwash reduces oral volatile sulphur compound levels. The outcome of this preliminary study indicates that the replacement of bacteria implicated in halitosis by colonization with competitive bacteria such as *S.salivarius* K12 may provide an effective strategy to reduce the severity of halitosis<sup>27</sup>. Reduced levels of volatile sulfur compounds produced by *Fusobacterium nucleatum* after taking *Weissella cibaria* have been observed by Kang et al<sup>28</sup>. The effect could be due to

hydrogen peroxide production by *W.cibaria*, causing *Fusobacterium nucleatum* inhibition.

## Prebiotics and Probiotics

Prebiotics when combined with probiotics have many advantages. Basically, prebiotics selectively stimulate the growth of probiotics, which is dose and strain dependent. Prebiotics serve as a selective growth substrate for the probiotics strain during fermentation, during the period of storage, or during its passage through the gut. These two combinations implant live microbial dietary supplements and create a congenial environment for their survival in gut flora. Thereby, this environment in gut flora improves healthy microbial balance. So, the combination of prebiotics and probiotics may have additive and synergistic effect in providing better oral health conditions.

Paster et al in an attempt to determine bacterial diversity in the human subgingival plaque by using culture-independent molecular methods have estimated that the total species diversity in the oral cavity ranges between 500 and 600 species. This number was further extended by Kazor et al, who detected 200 additional unknown species on the dorsum of the tongue, making the number of species in the mouth to reach 700. Lactobacilli make approximately 1% of the cultivable oral microflora<sup>38,43</sup>. The most common lactobacilli species recovered from saliva in a study by Teanpaisan and Dahlenwere *L. fermentum*, *L. rhamnosus*, *L. salivarius*, *L. casei*, *L. acidophilus* and *L. plantarum*. Three of them are probiotic strains used in dairy products. These findings indicate that lactobacilli as members of resident oral microflora could play an important role in the microecological balance in the oral cavity. These studies further demonstrated that lactobacilli strains with probiotic properties may indeed be found in the oral cavity.

## Contraindications

Because probiotics are live bacteria, immunocompromised patients will not be a candidate for any probiotics. People who are undergoing chemotherapy are not candidates, as well as those who present with HIV/AIDS. Other conditions also drive down the immune system, and those patients are not good candidates either. Often, these patients need oral biofilm management, and xylitol products are a better option.

## Summary and Conclusions

The interest in oral probiotics has been growing during the last decades. At least some of the probiotic bacteria used in various probiotic products may colonize the oral cavity during the time they are in use; thus, the effects of probiotic bacteria in the oral cavity are important to understand. Probiotic bacteria seem to affect both oral microbiota and immune responses. On the other hand, the extent to which bacteria in food or in food ingredients can influence relatively stable oral microbiota is difficult to predict. Thus, both research to unravel the mechanisms of possible probiotic action and long-term clinical trials are needed if probiotics are to provide a new scientifically proven means of preventing or treating oral diseases. Several health-promoting effects of probiotic bacteria are well

documented and there is no reason to restrict the use of probiotic products because their effects on oral health are not yet well understood; however, their recommendation for dental health purposes is not yet justified. Genetic modification of probiotic strains to suit the oral conditions is thus needed. Systematic studies and randomized control trials are therefore needed to find out the best probiotic strains and means of administration in different oral health conditions.

## References

1. Report of a Joint FAO/WHO Expert Consultation on Evaluation of Health and Nutritional Properties of Probiotics in Food Including Powder Milk with Live Lactic Acid Bacteria (October 2001). "Health and Nutritional Properties of Probiotics in Food including Powder Milk with Live Lactic Acid Bacteria". Food and Agriculture Organization of the United Nations, World Health Organization.
2. Hamilton-Miller, Professor J. M. T.; G. R. Gibson, W. Bruck. "Some insights into the derivation and early uses of the word 'probiotic'". British Journal of Nutrition 2003 (90): 845. doi:10.1079/BJN2003954.
3. Meurman JH. Probiotics: do they have a role in oral medicine and dentistry? Eur J Oral Sci. 2005; 113(3): 188-196.
4. Mach T (November 2006). "Clinical usefulness of probiotics in inflammatory bowel diseases". Journal of Physiology and Pharmacology : an Official Journal of the Polish Physiological Society 57 Suppl 9: 23-3.
5. Yan F, Polk DB (November 2006). "Probiotics as functional food in the treatment of diarrhea". Current Opinion in Clinical Nutrition and Metabolic Care 9 (6): 717-21. doi:10.1097/01.mco.0000247477.02650.51. PMID 17053425.
6. Reid G (September 2008). "Probiotic Lactobacilli for urogenital health in women". J. Clin. Gastroenterol. 42 (Suppl 3 Pt 2): S234-6. doi:10.1097/MCG.0b013e31817f1298. PMID 18685506.
7. Vanderhoof JA (November 2008). "Probiotics in allergy management". Journal of Pediatric Gastroenterology and Nutrition 47 Suppl 2: S38-40. doi:10.1097/01.mpg.0000338810.74933.c1. PMID 18931598.
8. Meruman JH, Stamatova I. Probiotics; Contribution To Oral Health. Oral Dis. 2007; 13:443-451.
9. Havenaar R, Huis Int Veld MJH. Probiotics: a general view. In: Lactic acid bacteria in health and disease. Vol.1 Amsterdam: Elsevier Applied Science Publishers, 1992.
10. Fuller R. Probiotics in man and animals. J Appl Bacteriol. 1989; 66: 365-378.
11. Caglar E, Cilder SK, Ergeneli S, Sandalli N, Twetman S. Salivary mutans streptococci and lactobacilli levels after ingestion of the probiotic bacterium *Lactobacillus reuteri* ATCC 55739 by straws or tablets. Acta Odontol Scand. 2006; 64: 314-318.
12. Caglar E, Kargul B, Tanboga I. Bacteriotherapy and probiotics' role on oral health. Oral Dis. 2005a; 11: 131-137.
13. Parker R B. Probiotics, the other half of the antibiotic story. Anim Nutr Health. 1974; 29:4-8.
14. Hatakka K, Ahola AJ, Yli-Knuuttila H, Richardson M, Poussa T, Meurman JK. Probiotics reduce the prevalence of oral Candida in the elderly - a randomized controlled trial. J Dent Res. 2007; 86: 125-130.
15. Kang M-S, Kim B-G, Lee H-C, Oh J-S. Inhibitory effect of *Weissella cibaria* isolates on the production of volatile sulphur compounds. J Clin Periodontol. 2006; 33: 226-232.
16. Kang MS, Na HS, Oh LS. Coaggregation ability of *Weissella cibaria* isolates with *Fusobacterium nucleatum* and their adhesiveness to epithelial cells. FEMS Microbiol Lett. 2005; 253: 323-329.
17. Gibson GR, Beatty EB, Wang X et al. Selective stimulation of bifidobacteria in the human colon by oligofructose and inulin. Gastroenterol. 1995; 108: 975-982.
18. Von Bultzingslowen I, Adlerberth I, Wold AE et al. Oral and intestinal microflora in 5-fluorouracil treated rats, translocation to cervical and mesenteric lymph nodes and effects of probiotic bacteria. Oral Microbiol Immunol. 2003; 18: 278-284.
19. Yli-Knuuttila H, Snaa I J, Kari K, Meurman JH. Colonization of *Lactobacillus rhamnosus* GG in the oral cavity. Oral Microbiol Immunol. 2006; 21: 129-131.
20. Haukioja A, Yli-Knuuttila H, Liomaranta V et al. Oral adhesion and survival of probiotic and other lactobacilli and bifidobacteria in vitro. Oral Microbiol Immunol. 2006a; 21: 326-332.
21. Burton JP, Chilcott CN, Tagg JR. The rationale and potential for the reduction of oral malodour using *Streptococcus salivarius* probiotics. Oral Dis. 2005; 11 (Suppl. 1): 29-31.
22. Busscher HJ, Mulder AF, van der Mei CH. In vitro adhesion to enamel and in vivo colonization of tooth surfaces by lactobacilli from a bio-yogurt. Caries Res. 1999; 33: 403-404.
23. Montalto M, Vastola M, Marigo L et al. Probiotics treatment increases salivary counts of lactobacilli: a double-blind, randomized, controlled study. Digestion. 2004; 69: 53-56.
24. Corcoran BM, Ross RP, Fitzgerald GF et al. Comparative survival of probiotic lactobacilli spray-dried in the presence of prebiotic substances. J Appl Microbiol. 2004; 96: 1024-1039.
25. El-Nezami HS, Polychronaki NN, Ma J et al. Probiotic supplementation reduces a biomarker for increased risk of liver cancer in young men from Southern China. Am J Clin Nutr. 2006. 83: 1199-1203.



# Knowledge and attitude regarding the use of conscious sedation for dental procedures among the interns of dental colleges in Chennai city – A cross sectional survey

Yamuna V<sup>1</sup>, Lalithambigai G<sup>2</sup>, Madan Kumar PD<sup>3</sup>

1 Intern,  
Ragas Dental College and Hospital,  
Chennai.  
2 Senior lecturer, 3 Professor and Head,  
Department of Public Health Dentistry,  
Ragas Dental College and Hospital,  
Chennai.

Received : 22.09.2015

Review Completed : 15.10.2015

Accepted : 20.10.2015

## ABSTRACT

**Aim:** Conscious sedation is one of the evolving techniques in dentistry. It is useful to deliver treatment to patients without discomfort and it is non-invasive. The use of conscious sedation is found to be increasing day by day in the dental practice. Hence the present study was conducted to assess knowledge and attitude regarding the use of conscious sedation for dental procedures among the interns of dental colleges in Chennai.

**Material and Methods:** A cross sectional web based survey was conducted among 123 interns of various dental colleges in Chennai. A questionnaire was used to collect the data from the study participants by creating a link in Google and responses were obtained. **Result:** Majority (96.7%) were aware that conscious sedation could be used as an alternative technique to achieve anaesthesia in delivering dental procedure. Although 87.8% of them have been taught about conscious sedation in their curriculum, most of them (83.70%) had not assisted dentists/ anaesthetists at the time of delivering conscious sedation. More than two third of the responders have not attended any Continuing Dental Education (CDE) programs regarding conscious sedation. **Conclusion:** Knowledge about the conscious sedation is less among the target population and their attitude for gathering information is high.

**Keywords:** Conscious sedation; Dental Interns; Knowledge; Attitude

## Introduction

Pain is one of the most common barriers that affect patients' behaviour to seek dental treatment. In dentistry there are various techniques ranging from non invasive to invasive, involved daily in the management of pain. Behavioural management and modification starts from the first appointment and includes both non pharmacological and pharmacological pain management methods. The non-pharmacological methods include verbal and nonverbal communications, desensitization, modelling, contingency management, audio analgesia, biofeedback, voice control, aroma therapy, humor, hypnosis, coping, relaxation implosion therapy and aversive conditioning.<sup>1</sup> Although these techniques are feasible, it will consume lot of valuable time of dentist and also have legal implications.

The pharmacological methods include premedication, conscious sedation, local anaesthesia and general anaesthesia. Local anaesthesia is widely used for various dental treatment like extraction of teeth, implant placement, root canal treatment, bone sounding, etc. but it has inherent drawbacks like pain, anxiety, failure to secure complete anaesthesia, needle stick injury, infection, trismus and nerve injury.<sup>2</sup>

Among the other pharmacological methods, General anaesthesia is indicated in patients with certain physical, mental or medically compromising condition, patients allergic to local anaesthesia, patients who have sustained extensive orofacial trauma, fearful, uncooperative and anxious patient.<sup>1</sup> Though the treatment success is high with general anaesthesia, it requires skilled, trained personnels and special equipments with hospital set-up to deliver it.

Due to various limitations in different techniques, a new technique has emerged to deliver successful dental treatment. Patients who have a real fear of dental treatment and those who are faced with the prospect of an unpleasant and possibly distressing procedure rightfully expect less stressful option for sedation. One such technique which was introduced early and gaining popularity in the present day is CONSCIOUS SEDATION.

According to American Dental Association, Conscious Sedation is defined as a minimally depressed level of consciousness that retains the patient's ability to independently and continuously maintains an airway and responds appropriately to physical stimulation or verbal command and that is produced by a pharmacological or non-pharmacological method or a combination thereof.<sup>3</sup>

Conscious sedation is indicated in patients who cannot cooperate, patients lacking psychological and emotional maturity and anxious patients. This technique utilizes nitrous oxide or midazolam and depresses the consciousness of the patients which makes dentists to deliver treatment without waste of time and without the demand of hospital set-up. The major limitation of conscious sedation, inspite of its advantages in dentistry, is that it is available only to the hands of trained anaesthetists and also has complications like cardiac arrest, methemoglobinemia and diffusion hypoxia.<sup>4</sup>

Since conscious sedation is riveting, furthering daily and a reassuring technique, its knowledge among the budding dentists is important. Therefore Dental Council of India introduced conscious sedation into the dental curriculum. Yet the live demonstrations and clinical experience are restricted to handful of postgraduate dentists of certain specialities.

Hence it is clearly necessary to find out what young dental students think about the use of conscious sedation in routine dental practice which is still an unanswered question. This has paved way to conduct the present study to assess the knowledge and attitude regarding conscious sedation among interns of various dental colleges in Chennai.

## Materials and Methods

A cross sectional web based questionnaire study was done among the interns of dental colleges in Chennai. The questionnaire containing eighteen questions to assess the knowledge and attitude about conscious sedation was



prepared. An invitational email was sent to ten Dental Colleges in Chennai. The invitational email included a link to the web survey (<http://goo.gl/forms/CZmH6lg7jA>). Voluntary consent was obtained from the responders. Remainder link was sent through email. A total of 300 interns were approached and among them 123 (41%) interns replied and their responses were collected directly in GOOGLE DRIVE. Data was analyzed using SPSS version 11.0 for frequency and percentages. Ethical clearance and permission to conduct the study was obtained from the college authorities.

## Results

In this study, a total of 123 interns participated out of which 20 were males and 103 were females. Table 1 shows the distribution of Dental Interns knowledge and attitude regarding conscious sedation. All responders were aware that local anaesthesia was the commonly used technique to deliver dental care. With regard to the common difficulties faced in various anaesthetic techniques, the options were equally shared by the respondents between anxiety of needle injury, failure to secure anaesthesia and complaints of persistent pain after the injection by the patient.

Majority of responders had come across the term conscious sedation and 87.8% of them have been taught about conscious sedation in their curriculum.

A large number of interns (96.7%) were aware that conscious sedation can be used as an alternative technique to achieve anaesthesia in delivering dental procedure. But among them only three fourth were aware about the applications of conscious sedation in dentistry. Protocol approved by Dental Council of India to use conscious sedation was not known to majority (80.5%) of the study population.

Wide range of confusion exists among the set-up used to deliver conscious sedation because one third opted for hospital set-up only and remaining two third for both clinic and hospital set-up. This confusion also extended regarding persons legally entitled to deliver conscious sedation.

Three fourth of interns (83.7%) have not assisted dentists/anaesthetists at the time of delivering conscious sedation and almost all the responders have not attended any Continuing Dental Education programs regarding conscious sedation. But at the same time many respondents were interested in gathering more information regarding conscious sedation. Among those interested, 68.6% use internet and remaining use textbook as source to gather information about conscious sedation. As to the complication and advantages of conscious sedation, the responders' opinion varied widely.

## Discussion

A key factor in delivering safe, effective, and pleasant dental care lies in efficient management of patient behaviour. It is important for a dental practitioner to perform quality oral health care in an anxious patient by

proper selection of sedation technique amongst the array of various non-pharmacological and pharmacological techniques recommended.<sup>1</sup>

In addition to tailoring various behavioral management techniques (BMT) to the individual patient, it is also important for dental practitioners to utilize techniques consistent with their level of professional education and clinical experience.<sup>5</sup> One such promising technique is conscious sedation which allows a dentist to work quicker and in a more focused manner, diminishing the chance of mechanical error and improving the quality of dental care with lesser dental appointments.

Knowledge of the perceptions of the dentist is useful in assessing awareness and misapprehensions regarding the same. This may serve as a guide for future research and understanding the barriers for using sedation in dentistry. There are very few studies reported worldwide regarding this aspect. Hence the present study assessed the knowledge and attitude regarding the use of conscious sedation for dental procedures among the interns of dental colleges in Chennai city.

Our study showed that Local Anaesthesia was the commonly used technique to deliver dental care to the patients. But it has many drawbacks like anxiety, pain, failure to secure anaesthesia and difficulty in administering it to children. Due to all these road blocks, it was essential to get introduced with and trained with more fascinating, advancing and promising technique – Conscious sedation. Introduction of conscious sedation in medicine especially in the field of dentistry pushes the field to much higher level. This helps to handle the uncooperative patients in easier way with lesser wastage of time.

The present study showed that 87.8% of responders were taught about conscious sedation in their curriculum similar to study done by Kumar VDet al.<sup>6</sup> Though it is present in current dental curriculum, its coverage was not appreciable for the emerging dentists to meet with the challenges, atleast in assisting dentists or physicians while delivering conscious sedation.

About 16.3% of interns have assisted dentists /anaesthetists at the time of delivering conscious sedation which was higher than study reported earlier.<sup>6</sup> In the present study only handful of dentist (4.1%) have attended "Continuing Dental Education" programs regarding conscious sedation. This reveals only a few institutions offer training in conscious sedation in its undergraduate course, in line with the recommendations of the American Dental Association.

To conclude, while the knowledge of students towards conscious sedation is less, the attitude of students in gathering information regarding conscious sedation is on the rise. Hence, in addition to concentrating the various aspects of conscious sedation in curriculum, demonstrations and hands-on procedure as diploma or

short term courses for conscious sedation will give deeper insight and experience to the emerging dentists and better equip them to handle pain in dentistry.

## References

1. Shobha Tandon. Textbook of Pedodontics. 2nd Ed, Hyderabad:Divyesh Arvind Kothari Paras Medical Publisher; 2008.
2. Stanley F. Malamed Handbook of Local Anesthesia. 6th Ed, Missouri: Elsevier publication; 2012.
3. American Dental Association (ADA): Guidelines for the use of sedation and general anesthesia by dentists 2012. ([http://www.ada.org/sections/educationAndCareers/pdfs/anesthesia\\_use\\_guidelines.pdf](http://www.ada.org/sections/educationAndCareers/pdfs/anesthesia_use_guidelines.pdf)) accessed on 17th August 2015

4. Ralph E. McDonald, David R. Avery Dentistry for the child and adolescent. 5th Ed, St.Louis:The C.V. Mosby Company; 2000.
5. American Academy of Pediatric Dentistry (AAPD): Guideline on behavior guidance for the pediatric dental patient. Pediatr Dent 2011; 34:170-182.
6. Kumar VD, Kiran YC, Babu NS, Jha S, Kavitha M. Assessment of Perceptions about Sedation in Dentistry amongst General Dental Practitioners, Dental Students and General Public - A Descriptive Cross-Sectional Study. Int J Sci Stud 2015; 2(12):127-130.

Table 1: Knowledge and attitude towards conscious sedation among Dentist

| Knowledge towards conscious sedation  | Gender     |             | Total         |
|---|------------|-------------|---------------|
|   | Males (%)  | Females (%) | Frequency (%) |
| Commonly used anaesthetic technique in dentistry  |            |             |               |
| 1. Local anaesthesia  | 20 (100)   | 103 (100)   | 123 (100)     |
| 2. General anaesthesia  | 0 (0)      | 0 (0)       | 0 (0)         |
| 3. Any other  | 0 (0)      | 0 (0)       | 0 (0)         |
| Set up is/are used to treat patients under conscious sedation   |            |             |               |
| 1. Clinic set up  | 4 (20.0)   | 6 (5.8)     | 10 (8.1)      |
| 2. Hospital set up  | 6 (30.0)   | 39 (37.8)   | 45 (36.6)     |
| 3. Both clinic and hospital set up  | 10 (50.0)  | 58 (56.3)   | 68 (55.3)     |
| Conscious sedation as an alternative technique to achieve sedation in dentistry                             |            |             |               |
| 1. Yes  | 19 (95)    | 100 (97.0)  | 119 (96.70)   |
| 2. No   | 1 (5.0)    | 3 (2.9)     | 4 (3.3)       |
| Awareness of Protocol prescribed by DCI   |            |             |               |
| 1. Yes  | 6 (30.0)   | 18 (17.4)   | 24 (19.50)    |
| 2. No   | 14 (70.0)  | 85 (82.5)   | 99 (80.5)     |
| Persons legally entitled to use conscious sedation to treat patients  |            |             |               |
| 1. Dentists only  | 0 (0.0)    | 2 (1.9)     | 2 (1.6)       |
| 2. Anaesthetists only   | 11 (55.0)  | 38 (36.8)   | 49 (39.8)     |
| 3. Dentists and anaesthetists   | 9 (45.0)   | 63 (61.1)   | 72 (58.5)     |
| Awareness about conscious sedation applications in dentistry  |            |             |               |
| 1. Yes  | 9 (45.0)   | 65 (63.10)  | 74 (62.20)    |
| 2. No   | 10 (50.0)  | 35 (33.9)   | 45 (37.8)     |
| The most common agent used in conscious sedation  |            |             |               |
| 1. Nitrous oxide  | 18 (90)    | 89 (86.4)   | 107 (87)      |
| 2. Halothane  | 2 (10)     | 14 (13.5)   | 16 (13)       |
| Interest towards gathering knowledge about conscious sedation   |            |             |               |
| 1. Yes  | 19 (95.0)  | 100 (97.0)  | 119 (96.70)   |
| 2. No   | 1 (5.0)    | 3 (2.9)     | 4 (3.3)       |
| Source of information about conscious sedation?   |            |             |               |
| 1. Internet   | 14 (70.0)  | 69 (66.9)   | 83 (68.6)     |
| 2. Textbooks  | 6 (30.0)   | 29 (28.1)   | 35 (28.9)     |
| 3. Any other  | 0 (0)      | 3 (2.9)     | 3 (2.5)       |
| Complications in delivering dental care to patients under conscious sedation                                |            |             |               |
| 1. Diffusion hypoxia  | 6 (30.0)   | 32 (31.0)   | 38 (30.9)     |
| 2. Methemoglobinemia  | 2 (10.0)   | 10 (9.7)    | 12 (9.8)      |
| 3. Transient amnesia  | 0 (0)      | 20 (19.4)   | 20 (16.3)     |
| 4. All the above  | 10 (50.0)  | 30 (29.1)   | 40 (32.5)     |
| 5. None of the above  | 2 (10.0)   | 11 (10.6)   | 13 (10.6)     |
| <b>Attitude towards conscious sedation</b>  |            |             |               |
| Common difficulty while using various anaesthetic technique for the delivery of dental care to the patients |            |             |               |
| 1. Anxiety of needle injury   | 11 (55.0)  | 38 (36.8)   | 49 (39.8)     |
| 2. Failure to secure anaesthesia  | 6 (30.0)   | 36 (34.9)   | 42 (34.1)     |
| 3. Patient complaints of persistent pain after the treatment  | 3 (15.0)   | 26 (25.2)   | 29 (23.6)     |
| 4. Any other  | 0 (0)      | 3 (2.9)     | 3 (2.4)       |
| Participation of dental students in CDE programs regarding conscious sedation                               |            |             |               |
| 1. Yes  | 0 (0)      | 5 (4.8)     | 5 (4.10)      |
| 2. No   | 20 (100.0) | 98 (95.1)   | 118 (95.9)    |
| Assistance for dental procedure done under conscious sedation   |            |             |               |
| 1. Yes  | 2 (10.0)   | 18 (17.4)   | 20 (16.30)    |
| 2. No   | 18 (90.0)  | 85 (82.5)   | 103 (83.7)    |
| Conscious sedation is more advantageous than other techniques in dental practice?                           |            |             |               |
| 1. Yes  | 13 (65)    | 98 (95.1)   | 91 (74)       |
| 2. No   | 7 (35)     | 25 (24.2)   | 32 (26)       |
| If yes, advantages in delivering dental care to the patients?   |            |             |               |
| 1. Useful to treat anxious patients at different ages   | 3 (15.0)   | 12 (11.6)   | 15 (14.4)     |
| 2. Non-invasive procedure   | 0 (0)      | 7 (6.7)     | 7 (6.7)       |
| 3. Relatively long procedures can be done safely  | 1 (5.0)    | 3 (2.9)     | 4 (3.8)       |
| 4. Increases patient comfort  | 0 (0)      | 6 (5.8)     | 6 (5.8)       |
| 5. All the above  | 11 (55.0)  | 61 (59.2)   | 72 (69.2)     |
| Technique preferred for anxious children in delivering dental care  |            |             |               |
| 1. Behavioural management like HOME   | 12 (60.0)  | 42 (40.7)   | 54 (43.9)     |
| 2. Conscious sedation   | 8 (40.0)   | 60 (58.2)   | 68 (55.3)     |
| 3. Any other  | 0 (0)      | 1 (0.9)     | 1 (0.8)       |

# ADVERTISEMENT

In God We Trust

Since 1986

## Blessy Dental Lab

**E. Shankar**

Dental Technician Regd. No.234

- ◆ **METAL FREE CERAMIC**
- ◆ **METAL CERAMIC**
- ◆ **VITALLIUM CROWNS**
- ◆ **ATTACHMENTS**
- ◆ **SOFT SPLINTS**
- ◆ **ALL ACRYLIC WORKS**

78 N.V.N. Nagar, Chennai-600 040.

Ph: 9841030972, 9444331717 E-mail : [blessydental@yahoo.co.in](mailto:blessydental@yahoo.co.in)

To Advertise Here

Contact: [emidasjournal@gmail.com](mailto:emidasjournal@gmail.com)

# PLACEMENT CELL

## **Wanted Resident Doctors for the following Clinics**

- **Identity Dental Centre**  
**Royappettah - 044 2813 3186**
- **Eswari Dental Centre**  
**Mogappair - 9884105711**
- **Kumaran Dental Clinic**  
**Jaffer Khanpet - 9841295911**
- **JN Multispeciality Dental Clinic**  
**Avadi - 9791121321**

**To Add Placement Details  
and Other Opportunity  
Contact: [emidasjournal@gmail.com](mailto:emidasjournal@gmail.com)**



# HANOCON 2015



# HANOCON 2015



# HANOCON 2015





# HANOCON 2015



# HANOCON 2015

## HEAD AND NECK ONCOLOGY CONFERENCE

The IDA Madras Branch along with SRM Institute of Medical Sciences (SIMS) and AO Chennai organized the 8th successful CDE programme titled "HANOCON"- Head and Neck Oncology Conference on 23rd August 2015 at Hyatt Regency, Teynampet. It was for the first time a collaboration of dental, ENT and Surgical oncology were represented on a single platform to share knowledge to enhance the care for Head and neck cancer affected patients.

The inauguration function of the CDE program was graced by eminent personalities like- Prof K. K Ramalingam (Director of KKR ENT Hospital) who was the chief guest, Prof K Sridhar (Vice president of SIMS Hospital) who was the guest of Honour, along with Dr Vidyaa Hari Iyer, President, IDA Madras Branch, Dr H. Thamizhchelvan, Honorary Secretary, IDA Madras branch. The function was made even more special with the felicitation of exemplary surgeons who have contributed and brought great laurels in the field of dental sciences, ENT and medical sciences. The felicitation of Dr Raju Sivasamy was done for his great efforts and work as the Vice president of SIMS Hospital. Prof Mohan Kameshwaran, Director of Madras ENT foundation was honoured at his occasion by Dr P Nataraj. Dr. S.M.Balaji was felicitated and honoured by Dr H. Thamizhchelvan for his extraordinary contribution to the dental fraternity and dental sciences. This occasion was made special with the presence and support from whole Executive Committee members of IDA Madras branch.

The welcome address was given by Dr Ranjan Kumar Mohopatra, Director, Medical Oncology, SIMS Hospital. It brought great pleasure and encouragement to listen to Prof K K Ramalingam who shared about his journey in treating head and neck cancer affected patients and the new reconstructive techniques that he had formulated. Prof Sridhar emphasized that the medical and dental specialities should co- exist, collaborate and co-operate in treating head and neck cancer to revolutionize and expand into the new horizon of treatment and care. Prof Mohan Kameshwaran emphasized that upcoming post graduate and practitioners should sought to attain knowledge to give the best treatment as a specialist. Prof SM Balaji expounded that the need of the hour is to co-exist and co-operate among all the specialities to become successful in treating oral cancer. Prof S Rajasundaram delivered the vote of thanks and promised that this new beginning of a collaborated forum and that HANOCON will be futuristic in taking head and Neck oncology care to the next level. He also appreciated IDA Madras Branch for the efforts made with regards to organizing it in collaboration with SIMS Hospital to mark a new beginning in the field of medical and dental sciences.

The total number of participant for this CDE programme was around 500 with around 46 speakers and panellist making it a great response with well informative lectures and panel discussions on latest concepts and approaches to treating oral cancer, secondaries, tongue and laryngeal cancers. The dental fraternity for the various discussions consisted of Prof KK Raja, Prof Rajesh, Prof Neelakandan, Prof Thamizh Chelvan, Prof Vivek Narayanan, Dr Jimson, Prof Muthusekar, Dr Malathi, Dr Mahesh. The various lectures and case discussions were very interactive and informative with information as to how to efficiently deal with head and neck cancer.

# CDE PROGRAMS

**9th CDE Program  
Awareness Workshop & Stakeholder Consultation  
On Mercury Phasing Out From Dental Sector  
September 2015 at Sree Balaji Dental College & Hospital**



**TOTAL MEMBERS ATTENDED:**



# CDE PROGRAMS

## Program

09.00 - 09.30 am : Registration  
 09.30 - 10.00 am : Inauguration  
 10.00 - 10.30 am : **Mercury Hygiene - Dentist Perspective**  
*Dr. Vidya Hari Iyer, President, IDA - Madras Branch*  
 10.30 - 11.00 am : **Status of Best Management Practices in Dental Sectors**  
*Mr. Mahit Bhatia, Programme Officer, Toxics Link, New Delhi*  
 11.00 - 11.15 am : Tea Break  
 11.15 - 11.45 am : **International & Regional Scenario with respect to Mercury in Health Care - Dr. Satish Sinha**  
 11.45 - 12.15 pm : **Mercury - An Occupational Threat**  
*Dr. Vidhya Venugopal, Professor, Dept. of Environmental Health Engineering, SRM, Chennai*  
 12.15 - 01.15 pm : **Panel Discussion**  
*Moderator Dr. A. Subbaya, Professor & HOD, Dept. of Conservative Health Dentistry, SRMCH*  
 01.15 - 02.00 pm : Lunch

## Registration Details

**Fees:**  
 Lecture & Panel Discussion  
 IDA Members : ₹ 400  
 Non Members : ₹ 500  
 Student Members : ₹ 300

**For Further Details Contact:**  
**Dr. Priya Prabhakar**  
 CDE Convener  
 Mobile: 9840875275  
 Email: drpriyaprbhakar@gmail.com

All Registrations along with the fees to be sent to:  
**Dr. H. Thamizhchelvan, Secretary, IDA Madras Branch,**  
 AB 61, 4th Street, Anna Nagar, Chennai - 600 040.  
 Phone: 044 - 4217 2715 | Mobile: 98841 05711  
 All Cheques to be drawn in favour of IDA Madras Branch



*Indian Dental Association  
- Madras Branch*

## 9<sup>TH</sup> CDE PROGRAM 2015

### Awareness Workshop & Stakeholder Consultation on Mercury Phasing Out from Dental Sector

**Date : 08.09.2015**  
**Time : 09.00am to 2.00pm**  
**Venue : Sree Balaji Dental College & Hospital, Chennai.**



## IDA Madras Office Bearers



**Dr. Vidya Hari Iyer**  
President



**Dr. H. Thamizhchelvan**  
Secretary



**Dr. Priya Prabhakar**  
CDE Convener

## Toxics Link Representatives



**Mr. Satish Sinha**  
Associate Director



**Mr. Mahit Bhatia**  
Programme Officer

## Introduction

Mercury is a toxic substance, which is neuro and nephro-toxicant in nature. When it enters into the environmental medium i.e. soil and water, it gets converted into its organic compound called Methyl Mercury, which has the potential to bioaccumulate and thus biomagnifying in nature. According to an estimate, Indian dental sector alone uses 65 tons of mercury annually, out of which 49 tons goes into the mouth, where as 16 tons enter into the environment as non-contact amalgam. This mercury enters the environment and then the food chain.

Recognizing the importance of the issue globally, a treaty has been signed, named Minamata Convention in the year 2013 by more than 195 countries. India has also signed the Treaty in September 2014. Besides, other mercury containing products, the Treaty also talks about the gradual phase down of mercury amalgam from the dental sector. With this background, a one day stakeholder awareness workshop is planned to create awareness among the dentist, dental students and general public about the problem of mercury toxicity and discuss the way forward.

## Objective

Create awareness among the dentists and general public about the mercury toxicity issue and its impact on environment and human health through regional meetings. Adoption of preventive measures by the dental colleges and private practitioners to restrict the mercury from entering the environment. Sharing the recommendation of these regional meetings with the Central Government for a policy change.

## Speakers



**Dr. Vidya Hari Iyer** graduated from Rajahmundry Dental College and went on to do her Diploma in Medicolegal Systems, Hospital and Health Care Management and Geriatric Care. She has authored a book "Going Green - A Manual of Waste Management for the Dental Practitioner" and has been awarded the Scroll of Honour for Biomedical Waste Management. She is the only Dental representative for Tamil Nadu Pollution control board since 2003. Dr. Vidya has been invited as guest speaker at many programs related to waste management. She has been felicitated for her services in Biomedical waste management and mercury hygiene by Dr. Meera Mustafa Hussain - Vice Chancellor, The Tamil Nadu Dr. M.G.R. Medical University. She has also conducted workshop on waste management and mercury hygiene for dental assistants.



**Prof. Dr. Vidhya Venugopal** is currently the Professor - Industrial Hygiene & Environmental Health, Department of Environmental Health Engineering, Sri Ramachandra University, Chennai. Dr. Vidhya Venugopal obtained her doctoral degree in Environmental Chemistry from the National Environmental Engineering Research Institute (NEERI) and did her post-doctoral research at Central Queensland University, Australia. Her job responsibilities include teaching Environmental Health Sciences, Industrial Hygiene, Environmental Management Systems and Chemical Toxicology for various disciplines. She has been actively involved in coordinating and implementing a Unified System for Biomedical Waste Management across the state of Tamil Nadu. Dr. Vidhya has been bestowed with numerous awards, honours and grants. Her rich academic experience has got her credit many national and international publications.



**Wing Commander, Satish Sinha (Retd.)** is the Associate Director, Toxics Link, a Non-profit Environmental organization working in field of Toxics and Waste. Wing Cdr. Satish has been associated with this research-based policy advocacy group since 2003 and has immense knowledge and expertise on environmental issues, especially in areas of municipal, hazardous & medical waste management and chemical safety. Wing Cdr. Satish has special expertise on the issue of E-waste and has worked extensively on the policy and legal aspects of E-waste and has also co-authored "E-Waste" published by TERI. He has been a key speaker on many national and international forums discussing environmental concerns and is a key advocate of finding sustainable solutions.



**Mr. Mahit Bhatia** is currently working as a Programme Officer in "Toxics Free Healthcare" department of Toxics Link NGO, New Delhi. Mr. Mahit has played a key role in developing specific campaigns on environmental issues and with policy analysis and advocacy. He has planned and implemented projects on bio-medical waste management in various parts of India. He has undertaken independent research on environmental issues, analysed information and data. He has also been instrumental in engaging with stakeholders and NGO partners and forming networks. He has Represented Toxics Link in various regional and national forums.

Page 38

e-MIDAS Chennai/Volume:2/Issue:3/Pages1-46/October2015

# CDE PROGRAMS

**10th CDE Program  
Indian Dental Association and ALKEM Laboratories  
September 2015 at Hotel Savera**



**TOTAL MEMBERS ATTENDED:**

# CDH ACTIVITIES

## **REPORT OF THE DENTAL SCREENING CAMP AT SBOA JUNIOR COLLEGE, ANNA NAGAR, CHENNAI - 600 101**

A One day Mega Dental Screening camp was conducted at the SBOA Junior college on 21.8.15. The programme was organised by the Indian Dental Association - Madras Branch along with the Rotary club of Madras North. The Tamil Nadu Government Dental College, Thai Moogambigai Dental College and Sri Ramachandra Dental College took part in this Mega dental screening programme. The total of 9967 school children were screened starting from Kindergarten to XII std.

The census of the total students screened by the Dental Colleges participated in the screening programme is as below:





# CDH ACTIVITIES



Tamil Nadu Government Dental College: 4594

Thai Moogambigai Dental College: 1598

Sri Ramachandra Dental College: 3775

Total: 9967

# CDH ACTIVITIES

## REPORT OF THE DENTAL SCREENING CAMP AT SRI PADMA SARANGAPANI SCHOOL, VIRUGAMBAKKAM, CHENNAI

IDA Madras Branch is association with Rotary Club of Chennai Sun City and SRM Dental College, Ramapuram organised a dental camp at Sri Padma Sarangapani School, Virugambakkam. A Total of 247 screening and 11 Treatment was done at the venue.



# UPCOMING EVENTS

**Month: November 6 - 8**

**Event : International Global Dental Meet 2015**

**Contact Person: Dr. K.K. Raja - 9840032950**

## MIDAS FEST 2015

### Scientific Convention

**Venue : Chettinad Dental College & Hospital  
Date : November 26 & 27**

### Sports Meet

**Venue : SRM Kattankulathur Dental College  
Date : December 12 & 13**

### Cultural Fest

**Venue : Saveetha Dental College & Hospital  
Date : December 19 & 20**